

VIII. *On the Regeneration of Nerves.*

By ROBERT KENNEDY, *M.A., B.Sc., M.D., Glasgow.*

Communicated by Professor MCKENDRICK.

[*From the Western Infirmary, Glasgow, and the Zoological Laboratory of the University of Glasgow.*]

Received January 7,—Read February 11, 1897.

[PLATES 4-9.]

CONTENTS.

	Page
I. Historical Introduction	258
II. Cases of Secondary Suture of Nerves	262
1. Of median and ulnar six-and-a-half months after division	262
2. Of median three months after division	265
3. Of median and musculo-spiral several weeks after interruption at seat of fracture of humerus	267
4. Of ulnar eighteen months after division	269
III. Deductions from results of operation	271
IV. Microscopical examination of the portions removed previous to suture	274
1. Methods	274
2. Microscopical appearances	274
<i>a.</i> Central ends	275
<i>b.</i> Peripheral ends	276
<i>c.</i> Intercalary cicatricial segments	277
<i>d.</i> Portions compressed at seat of fracture	278
V. Deductions from the microscopical appearances	280
1. Degeneration	280
2. Regeneration of nerve fibres in the peripheral segment, while still sepa- rated from the central segment	282
3. The origin of the young fibres	283
4. Characters of the young fibres	285
5. Cicatricial intercalary segments	286
VI. General Conclusions	287
VII. Bibliography	287
VIII. Explanation of Plates	297
MDCCCXCVII.—B.	28.8.97



I.—HISTORICAL INTRODUCTION.

THE view expressed by GALEN that nerves once divided are incapable of undergoing repair, was that universally accepted until the latter part of last century. It is true that GUY DE CHAULIAC* speaks of the perfect restoration of divided nerves, but as he speaks at once of nerves and tendons, it is doubtful whether we can accept his remarks as really referring to nerves.

CRUIKSHANK (2) was the first to show that reunion is possible. He divided the vagus of the right side in a dog, and three weeks later excised a portion from the nerve of the opposite side, and the animal made a perfect recovery. Three weeks later he killed the dog, and found both nerves reunited. The results of his investigations were communicated to the Royal Society on 13th June, 1776, but his paper was not printed until nineteen years later. His preparation, however, was placed in WM. HUNTER'S Museum, and was the means of stimulating others to further researches. I found this preparation in the Museum in Glasgow University, and was easily able to identify it from the drawing published with the paper.†

CRUIKSHANK himself held on physiological grounds that the nerves in his preparation were united by nerve substance, but the prevailing opinion was that the bond of union was composed of connective tissue. FONTANA (3), MICHAELIS, HAIGHTON (6), MEYER (7), and PRÉVOST (10), supported the former view, on the ground of their own researches, while MONRO (4), ARNEMANN (5), and others held to the latter view. The work of STEINRÜCK (14) which appeared in 1838, set the matter at rest, for from that time the possibility of reunion of nerves by nerve substance is admitted by almost all observers.

With NASSE (15) a new field of investigation was begun, for that observer discovered that after section of a nerve, degeneration of the primitive fibres occurs. He, however, only examined the seat of section, as also did GÜNTHER and SCHÖN (16) in the following year, and STANNIUS (18) a few years later, while he observed on one occasion degeneration of the ultimate ramifications of the nerve in the muscular fibres after section of the stem, did not follow up the clue, but left to WALLER (20, 22 to 29) the discovery of the inevitable degeneration of the whole peripheral segment after section of a nerve, and the enunciation of the law of dependence of the nerves for their nutrition on trophic centres. WALLER'S view is that after section of a nerve, the whole nerve fibre is destroyed, and that it never can recover its structural characters or functional properties, and that the young nerve fibres are new formed structures

* GUIDO DE CAULIACO (1), p. 114, "Ego vidi et audivi in multis nervos et thenanton incisos; et eos ita restauratos cum sutura et aliis auxiliis, quod erat postea incredibile ipsos fuisse incisos."

The numbers in parenthesis refer to the Bibliography, p. 287.

† My thanks are due to Professor YOUNG for granting every facility for and help in identifying this preparation. The delay in printing CRUIKSHANK'S communication until after the death of HUNTER accounts for the history of the preparation not having been inserted in the Catalogue of the Museum.

always found lying between the old degenerated remains ; that they are never found till reunion has occurred ; and that they start in the intermediary uniting segment, and travel on to the ultimate ramifications of the nerve.

This view was widely accepted, but the length of time required for such a process of regeneration was found not to accord with clinical observations made by PAGET (30), and experimental observations by SCHIFF (31) and by BRUCH (32), and these observers held that nerves must also be capable of undergoing repair by first intention, to account for the rapid return of function, which they found after certain cases of nerve section.

The view advanced by WALLER that the peripheral segment of a divided nerve is incapable of being regenerated, until reunited to the central segment, had been received without contradiction. PHILIPPEAUX and VULPIAN (38, 39), however, while corroborating the ultimate degeneration as a result of separation of a nerve from its centres, found that the peripheral segment can, even while remaining separate from the central segment, undergo reparation. Not only so, but a portion of the lingual nerve transplanted under the skin of the inguinal region in dogs contained new fibres after six months (47). These observers held that the axis-cylinder was not destroyed during degeneration, and that restitution consisted simply in a reaccumulation of the myeline, and that, therefore, restitution was simply a restoration. Their results were met by much opposition, SCHIFF (41), LANDRY (42), and AMBROSOLI (43) writing at the time in opposition to them, and since, almost all the writers have opposed their conclusions, some maintaining with RANVIER (102) that the regeneration which they observed was due to connecting strands of tissue between the proximal and distal ends, strands which they had failed to observe, and even VULPIAN (77, 86) himself, some years later, withdrew from his former position, admitted that what had been seen were not regenerated fibres, and denied the possibility of autogenetic regeneration of nerves. Their conclusions, however, are supported by MITCHELL (80), and more recently by BOWLBY (146).

The general opinion was against the possibility of reunion of nerves by first intention, when in 1864 the cases of nerve suture in man by NÉLATON (54), and LAUGIER (55) were published. In NÉLATON'S case a neuroma was excised from the median in the arm, and return of function was established in a few days, and in LAUGIER'S case the median was completely divided in the forearm, was sutured, and function returned in a few days.

The interest in the subject of nerve regeneration was greatly increased by the publication of these cases, and several workers were induced to commence experimental research to investigate the matter. EULENBURG and LANDOIS (56, 60), from their investigations in animals, strongly opposed the view that nerves could heal by first intention, and thought the employment of suture a highly dangerous proceeding. MAGNIEN (61), on the other hand, found no harm from the employment of suture, and

in two cats he found return of function in a few days after section and employment of suture.

Further doubt was thrown on the value of the clinical experience of early return of function after nerve suture, by the experiences of RICHET (62) and of LÉTIÉVANT (73, 82). RICHET observed a case in which, after section of the median nerve, sensation remained in the distribution of that nerve; and ARLOING and TRIPIER (70) explained the case by showing that in the dog there is in the skin an anastomosing network of the ultimate fibrils of all the nerves supplying the paw, and that no part of the skin is exclusively supplied by a single nerve. LÉTIÉVANT, again, found that after section of the median nerve without reunion, movements were developed in the hand which resembled those performed by the muscles supplied by the divided nerve, and showed that these movements were imitations by neighbouring muscles, whose supply remained intact, of the movements performed by the paralysed muscles. He also showed that, though the sensory supply of a region is cut off, sense of touch may remain by mediate communication with other nerves. TILLMANN (123), again, supposes that from neighbouring intact nerves, filaments may grow out into the anæsthetic region; and REMAK (87), that anastomosing fibres may develop after nerve section, in a way comparable to the development of the collateral circulation after occlusion of an artery.

Thus the clinical experience of early return of sensation after nerve section has been discredited as a proof of the reunion of the nerve. VANLAIR (122), for example, considers that if after nerve section sensation returns in a very short time, it is due to anastomosing fibres, and the short period of anæsthesia is due to the numbing effects of hæmorrhage; if more slowly, that it is due to supplementary supply; and that if a very long time elapses, then it is due to regeneration of the divided nerve.

But the cases of secondary suture published speak strongly against the slow process of regeneration from the central end. One of the first of these was a case published by JESSOP (75), where the ulnar nerve had been cut across above the wrist nine years before the operation of suture. Before the operation there was total loss of sensation and motion in the region supplied by the ulnar. The hand was thin and the palm hollowed out. The cicatrix uniting the ends was excised and the nerve sutured, and eight days after the operation sensation began to return, and in eight days more had returned everywhere, except at the tips of the fingers. A similar case was published by LANGENBECK.* In his case the sciatic had been cut across two and a half years before the operation, and there was total anæsthesia, and yet sensation began to return three days after the operation. Also OGSTON (120) performed secondary suture of the ulnar in a case in which the nerve had been cut long enough to produce the characteristic atrophy and claw-hand, and in which there was total loss of sensation and motion, and yet, a week after the operation, the return of sensation was determined.

* After WOLBERG (127), p. 341.

These and similar cases in which sensation remains totally lost before operation and long after the date of section of the nerve, but returns in a few days after the operation, cannot be explained on the theories mentioned, and must indicate a reunion of the nerve, and re-establishment of conductivity; and these cases would indicate that nerves, though long divided, must be capable of very early reunion, when placed in suitable conditions for that to take place.

At present the views of the histological process of regeneration are divisible into two groups:—

1st. The view established by RANVIER (81,102), and closely coinciding with that of WALLER, that the peripheral segment of the nerve takes no part in the process of regeneration, but that the latter is effected entirely by growth of new axis-cylinders from those of the central end of the nerve, the peripheral segment acting merely as a guide for growth to the end organs. This view is very widely accepted, and is supported by the histogenetic researches of KÖLLIKER (109) and HIS (111, 144, 147). It has been recently supported by HOWELL and HUBER (156), STROEBE (158), and NOTTHAFFT (159), who, however, find that the envelopes of the axis-cylinders are supplied from elements in the peripheral segment.

2nd. The view that the new fibres are derived from elements in the distal segment, and that the young fibres thus formed become attached to the fibres of the central segment, and thus restore conductivity. Recently BÜNGNER (150) has adopted this view, and holds that the young fibres are derived from the protoplasm and nuclei of the interannular segments. These form spindle-cells which unite end to end, and form protoplasmic threads, which soon show longitudinal striation, the beginning of the axis-cylinder. The new myeline sheath is formed from the outer layer of the young fibres, and also partly by absorption of the old myeline. The old sheath of SCHWANN disappears, and the new is derived from the endoneurial tissue. The nuclei of the new sheath of SCHWANN, are the direct descendants of the nuclei of the old, and have clearly the value of neuroblasts. This view coincides with the histogenetic researches of BALFOUR (93, 121) and MILNES MARSHALL (97).

According to the first view, the process of regeneration requires for its accomplishment a more or less long period of time, depending on the length of the peripheral segment. Thus VANLAIR (160) estimates the rate of growth from the central end to be from 0.3 millim. to 1 millim. daily, after section and immediate perfect coaptation. According to the second view, the time is not necessarily long, seeing that the material for the work of regeneration is already laid down along the whole length of the peripheral segment. Thus the published cases of secondary suture, with speedy return of sensation, are enigmatical on the first view, but are capable of explanation on the second view.

II.—CASES OF SECONDARY SUTURE OF NERVES.

My observations were made on four cases,* in three of which the nerves had been accidentally divided some time previously, and functional reunion had not occurred; while in one the nerves were functionally interrupted by compression at the seat of a fracture. The cases were as follows:—

Case I.—Division of the ulnar and median nerves in the forearm.

Case II.—Division of the median nerve in the forearm.

Case III.—Interruption of the median, ulnar, and musculo-spiral nerves, resulting from a fracture at the elbow joint.

Case IV.—Division of the ulnar nerve in the forearm.

These cases, therefore, presented seven injured nerves. In the cases of division, I performed the operation of secondary suture, and in that of compression at the seat of fracture, dissected the nerves from their adhesions, and removed the compressed portions from the median and musculo-spiral, and sutured. In every case the portions removed were preserved for microscopical study.

Case I. (Plate 4, figs. 1 and 2.)

A boy, aged 16 years, received a wound with a piece of glass, on the front of the right forearm in its middle third. The wound was deep, and bled freely. It was sutured, and healed in about eight weeks, but by that time it was apparent that damage had been done to the nerves, as the hand was paralysed and sensation lost. Soon atrophy manifested itself, and the boy was unable to return to his work. He came for advice on 3rd March, 1894, fully six months after the accident, and his condition was found to be as follows:—

A cicatrix, 13 centims. in length, extended across the middle third of the front of the right forearm, obliquely from above downwards and inwards, crossing almost the entire breadth of the forearm. The lower and inner third of this cicatrix was red, and painful when firmly pressed; the middle third was extremely red, and prominent at its junction with the inner third, and its surface was thin and very tender even to the slightest touch; the upper and outer third had the appearance of an ordinary cicatrix. On moving the fingers, the cicatrix was found adherent to the muscles. The muscles of the forearm were atrophied, the right forearm being everywhere about 1 centim. less in circumference than the left at corresponding levels.

The trophic changes in the hand were well established. The skin was smooth red, and shining, and the flexures but little marked. There was a raw surface, without signs of healing, on the inner side of the first internode of the fifth digit;

* I owe to DR. PATTERSON my sincere thanks for permission to perform these operations in his ward in the Western Infirmary, Glasgow, and also for valued suggestions thereon.

this was the result of a burn received two weeks previously. The nails had a corrugated surface. The hand was colder than the left. There was great atrophy of the small muscles, the palm being hollowed out and the thenar and hypothenar eminences replaced by hollows.

The attitude and movements of the hand were those characteristic of section of the median and ulnar nerves. Thus all the fingers were held flexed at the two interphalangeal, and overextended at the metacarpo-phalangeal joints. The fingers could be passively extended, but voluntarily only to a slight extent, and in both cases only with accompanying flexion of the hand at the wrist. The hand was carried semiflexed at the wrist, simulating wrist-drop, but could be voluntarily straightened, although it could not long be held in that position, as a painful feeling was soon developed. He could also perform lateral movements of the hand at the wrist. The hand could only be partially closed, and when he attempted to extend his fingers keeping the wrist straight, only the first phalanges responded, the two distal remaining flexed. The movements of adduction and opposition of the thumb, and abduction of the fingers were impossible. With the hand dynamometer, he registered with the right hand 4 kilos., and with the left 16 kilos. The small muscles of the hand tested electrically gave no response to the faradic current, but responded to the galvanic current.

The condition of sensation was as follows. There was pain elicited by pressure over the terminal phalanx of the thumb; absolute anæsthesia, even for touch, in every part of the fifth and fourth digits; very slight sensation, but none for pain, as tested by pricking the skin with a pin, on the third digit and palmar aspects of the second and first; total anæsthesia of the palm and of the ulnar side of the dorsum of the hand; and normal sensation on the radial side of the dorsum of the hand, and over the thenar eminence and dorsal aspects of the first and second digits.

On 15th March, 1894, exactly six and a half months after the accident, I performed the operation of secondary suture. The median nerve was laid bare at the seat of section, and the two ends of the nerve were found united by a dense cicatricial mass, somewhat thicker than the nerve, and about 1.5 centim. in length. This cicatricial mass lay under the middle third of the skin cicatrix, which was found at the examination to be so very tender. The nerve itself was much thicker than a normal median nerve.

The ulnar nerve was next exposed through the same incision. It was found similarly hypertrophied, but the ends were separated about 2 centims. The central end lay about the level of the tender inner and lower third of the cutaneous cicatrix, and presented a hard bulb measuring about 1.5 centim. in length and 1 centim. in transverse diameter. The peripheral end lay at a lower level than the cicatrix in the skin, was not so much hypertrophied, and presented a bulb about half the size of that on the central end. It lay surrounded by loose connective tissue.

The cicatrix on the median was excised at its junction with the ends of the nerve,

and while the surface exposed at the central end showed nerve substance, that on the peripheral presented a homogeneous aspect. On removing an additional slice from the latter, nerve substance was exposed, and the section presented an appearance similar to that of the central end. The bulb on the central end of the ulnar was then cut off, and then the smaller bulb from the peripheral end, the sections in both cases exposing nerve tissue. Two sutures of chromic catgut were passed through each of the nerve ends by means of a flat needle, the plane of the needle being kept parallel to the course of the nerve fibres in order to inflict as little damage as possible. The hand and forearm were then fully flexed, and the sutures tied. The median came together easily, but the ulnar ends could not be brought together nearer than about 6 millims. The forearm and hand were then fixed fully flexed in a splint.

Three days after the operation, the first sign of returning sensation appeared; for on pinching the tip of the little finger, while the patient's head was covered, he cried out with pain. On the following day, he recognised the little finger when touched, and felt pain when it was firmly grasped or pricked with a pin. On the ninth day, the wound was dressed for the first time, and the patient stated that he felt his hand much stronger than before the operation. The improvement in sensation was maintained. On the nineteenth day, relaxation of the extreme flexion was begun gradually, and a more careful examination made of the condition of sensation. It was then found that he localised correctly all parts of the fingers touched, unless when the touches were slight, when he occasionally mistook the finger touched, and occasionally failed to feel a gentle touch on the little finger. The sore on the first internode of the little finger was now quite healed, and the operation wound was healed, except at the extreme ends, through which drainage had been made. Towards the end of the first month, the sensation had still further improved; for now he located correctly the gentlest touches, and responded quicker than he did at first. The limb had now been gradually extended, and the fingers, also, had now been fully extended by firm bandaging to the splint. He could also at this time partially close and again open the hand. Electrical treatment of the hand was then commenced. With the positive pole applied above the wrist over the respective nerves, and the negative to ZIEMSEN'S points over the small muscles, there were no contractions with the faradic current, but with a moderate galvanic current there were distinct contractions of the small muscles of the thumb; but only very slight contractions could be detected in the other small muscles. By a month and a half from the date of operation, the electrical condition had improved; for now, while all the small muscles responded to the galvanic current, the small muscles of the thumb gave contractions with the faradic current. There was also a notable return of power in the hand, as his grasp was appreciable. He was able to write legibly, which he was quite unable to do before the operation. By two months, the appearance of the skin had improved, and he was able to open and close the hand; but beyond a slight degree he could not

oppose the thumb. The cicatrix of the original wound, which was so red and tender before the operation, had now the appearance of an ordinary cicatrix, and had lost its tenderness. In the fifth month, he stated that he found no difference in sensation between the two hands, and that the hand was useful, although he was still unable to perform the more delicate movements; and this was explained by the persistent weakness of the opponens pollicis muscle. Despite the improvement in power, the atrophy of the palm and of the thenar and hypothenar eminences was still distinct, though less. The patient was last seen seven months after the operation, and at that time the improvement in sensation and motion was maintained, and the grasp of the hand much stronger. The sensation of the hand was perfect, and the appearance of the skin much improved; but there was still marked atrophy of the small muscles. The improvement in grasp up to that time is shown in the following table, taken with the hand dynamometer:—

Date.		Right.	Left.
March 3 . . .	Before operation	kilos. 4	kilos. 16
„ 15 . . .	Operation		
May 1	2	
„ 8	4	
„ 16	7	
June 21	8	16
October 19	14	29

Case II.

A man, 37 years of age, a carpenter, on 20th November, 1894, received a deep wound with a chisel on the right forearm, transversely, just above the wrist in front. The wound was not stitched, and was said to have healed in about a fortnight without suppuration. Immediately after the accident he noticed loss of sensation in the thumb and index and middle fingers. Sensation did not return, and the hand being useless, he sought advice on 28th February, 1895. His condition then, three months and eight days after the accident, was as follows:—

On the right forearm there was a linear cicatrix, 2·5 centims. in length, situated transversely above the wrist in front. Through this cicatrix a dense oval swelling, about the size of an almond, could be felt in the middle line of the forearm, and on applying pressure a tingling sensation shot up the arm and down into the hand. The skin, especially of the front of the index finger, thumb, and outer half of the palm, was smoother than is natural, and the flexures were greatly diminished. There was marked atrophy of the thenar eminence. The index and middle fingers could not be fully extended, nor could they be brought into contact with the palm; and there was considerable loss of power of flexion of the thumb, and the movement of opposition was impossible.

The condition of sensation was the following:—Total anæsthesia on the anterior aspects of the thumb, index, and middle fingers, and on the outer half of the palm; only obtuse tactile sensation on the outer side of the ring finger and over the thenar eminence. On pricking with a pin the palmar surfaces of the thumb, index, middle, and outer half of the ring fingers, no pain or other sensation was felt.

On 28th February, 1895, the median nerve was exposed by a longitudinal incision, 5 centims. in length, over the seat of injury. The nerve was found hypertrophied, and the ends united by a dense mass of cicatricial tissue, about 2 centims. in length and 1·5 centim. in greatest breadth, but flattened antero-posteriorly. This mass was excised at its junction with the nerve, and the sections exposed at the ends of the nerve showed points of what appeared to be nerve substance, but these were separated by dense white tissue. Two sutures of chromic catgut were passed through the whole thickness of the nerve, and the ends drawn together, and this was easily effected when the hand was fully flexed. The wound was closed, and no drainage used, and the limb bandaged to a splint with the hand fully flexed.

Two days after the operation sensation commenced to return. The sense of touch was present on the palmar aspects of the fingers and thumb, and a pin thrust into the palmar aspect of the thumb was felt as a painful sensation; but sensation was still vague. By the ninth day sensation was much improved, and by the thirteenth day pain was felt from the prick of a pin in the palmar aspects of all the affected fingers and in the thumb, and by the seventeenth day there was still further improvement. From this time the hand was gradually relaxed, and, finally, about the fourth week, when got into the extended position, the splint was discarded. A fortnight later there was distinct improvement in the muscular power of the hand. Towards the end of the second month (24th May) his sensation had further improved, and both touch and sense of pain were quite distinct, although not yet felt by the patient so distinct as in the other hand, but the point of the index finger was not so sensitive as the other parts of the median distribution. The improvement in the muscles was very decided; for not only had the atrophy of the thenar eminence in great part disappeared, but the movement of opposition was now so well developed that he was able to touch the tip of the middle finger with the tip of the thumb. At the end of six months, there was still further progress. Localisation of touch was perfect for all the parts concerned, and there was much improvement in the sensation of the last phalanx of the index finger; but even yet the patient found sensation less acute than in the sound hand. The grasp was almost as good as that of the left hand, and the movement of opposition was still further improved, since now he could touch with the thumb the tip of the ring finger. What prevented him from having as perfect use of his hand as formerly, was his inability to flex completely the terminal phalanges of the index and middle fingers. Thus, when he closed his hand, the tips of these fingers did not come sufficiently into the centre of the palm to enable him to grasp firmly smaller objects; but for larger objects his

grasp was as firm as that of any average hand. He had already some time since returned to his work, being able to use his hand. At the end of nine months the condition was further improved. He could distinguish with each finger the difference between the smooth and rough side of sand-paper. The atrophy of the thenar eminence had not only disappeared, but the eminence was even slightly greater than that of the left hand, and he was able to pick up the smallest piece of paper between fingers and thumb, although at six months he could only pick up a coin. At the end of a year, there was still further improvement, as he could now oppose the thumb to the little finger, but the grasp for smaller objects was still defective from his inability to flex completely the terminal phalanges of the index and middle fingers, although it was better than at nine months. His sensations of touch, pain, and thermic difference were correct, although not felt quite so clearly as in the left hand. As showing the degree to which the grasp had improved compared with that of the left hand, the dynamometer reading is of importance. One year and four months after the operation, with the right hand he registered 54 kilos., and with the left 58 kilos. (Plate 5, figs. 1 and 2.)

Case III. (Plate 6, figs. 1 and 2.)

A girl, aged 6 years, sustained a fracture of the left elbow joint from a fall. The limb was fixed in splints, which were removed at the end of four weeks. Her hand was then found to be anæsthetic and paralysed. On 12th December, 1895, eight weeks after the accident, I first saw her, and found her condition to be as follows:—

The internal condyle at the elbow joint was thickened, but otherwise the appearance of the joint was normal. The joint, however, only permitted a slight range of voluntary movement, and even under chloroform this range could not be much increased on forcible passive movement. The child carried the forearm flexed at a right angle, and the supinator longus was felt firmly contracted. Supination and pronation could not be voluntarily performed, but were easily accomplished passively. The hand was carried flexed, and could not be straightened, its range of movement being very limited. Voluntary motion was abolished. The first phalanges of the fingers were extended; the second and terminal, flexed. The first phalanx of the thumb was extended; the terminal, flexed. By passive movement the two distal phalanges of the fingers could be extended, only when the first were flexed. The forearm was wasted only to a degree appreciable by measurement; but the hand showed distinct trophic changes. Thus the dorsum was unnaturally smooth and wasted, and on the palmar aspect, and especially at the tips of the fingers, the skin was smooth and glossy, and on the palm the flexures were very indistinct. The small muscles were atrophied, giving a scooped-out palm, and hollows in place of the thenar and hypothenar eminences. Voluntary movement of the fingers was scarcely appreciable, but the slightest degree of flexion and extension could be detected.

With the faradic current the muscles of the forearm and hand gave no response ; but with the galvanic, good contractions. Sensation in the forearm was normal ; but neither touch nor the prick of a pin could be felt in any part of the hand, except over the outside of the first metacarpal bone, extending over the thenar eminence for a short distance in a less distinct degree.

On 13th December, 1895, the musculo-spiral nerve was exposed by an incision about 9 centims. in length, crossing the bend of the elbow. The nerve exposed to view was much thickened, and, a little below the bend of the elbow, where it divides into radial and posterior interosseous, it was firmly bound down by, and adherent to cicatricial tissue. This nerve exposed, the wound was temporarily closed, and the elbow joint then excised through a single incision behind. The ulnar nerve was next laid bare from the deep surface of the internal flap. The ulnar was also considerably hypertrophied, and firmly adherent at the level of the joint. It was freed from its adhesions. The median nerve was then exposed by an incision in front. It also was hypertrophied, and firmly adherent to the surrounding cicatricial tissue. It was dissected from its adhesions, but these being very intimate, the portion which seemed to be most involved was excised, that portion measuring about 12 millims. in length. The ends were then brought into apposition, which was easily effected after the excision of the elbow joint, and sutured with two chromic catgut sutures, passed through the whole thickness of the nerve. The musculo-spiral was then dissected from its adhesions, and as these were very intimate at its point of bifurcation into its two branches, the radial was divided about 6 millims. from its origin and the posterior interosseous about 3 millims. from its origin. The terminal portion of the musculo-spiral was then removed about 12 millims. from its bifurcation, and the two peripheral ends united to the central end of the musculo-spiral with chromic catgut. The wounds were then washed and sutured and drained with catgut. The limb was then fixed in a splint with the forearm semi-bent.

The dorsum of the hand, the only part exposed, was tested daily for the first sign of returning sensation ; but there was no change till the fourth morning after the operation, when there was an indication of improvement, in so far that some sensation, produced by pricking with a pin, was found extending downwards from the wrist, but only for a short distance. There was no further change till the seventh day, when the sensation had travelled down to the level of the mid-transverse line on the dorsum of the hand. There was also a point on the inside which was sensitive. On the following day there was sensation on the inside as far as the head of the metacarpal bone, and also a further extension on the outside. Pricking the skin of the palm with a pin caused the child to cry with pain. On the ninth day the same conditions obtained, but the child could as a rule locate the region pricked, but occasionally made a mistake. On the eleventh day there was obscure sensation in the fingers. The improvement continued, and on the seventeenth day the wounds were dressed and found healed, except at the points where they had

been drained. The arm was put on a rectangular splint, and the fingers bandaged out straight. The sensation had now so far improved, that the child could locate the finger pinched, although occasionally she made a mistake. At the end of six weeks, the last occasion upon which the patient was seen, the sense of pain on being pricked with a pin had returned in the little finger, and was quite distinct in the palm, but the other regions of the hand were still insensitive to pain. There was no return of motion, and the electrical reactions remained as before the operation.

Case IV. (Plate 5, fig. 3.)

A woman, aged 29 years, sustained a cut with a piece of glass on the right forearm, about 2.5 centims. above the wrist, extending from the front round the inside. The wound was stitched and healed without trouble, but she soon discovered that she had lost sensation in the little and ring fingers. Shortly afterwards the little and ring fingers and the palm of the hand began to waste, and the skin to assume a smooth glossy appearance. I saw her for the first time on 23rd January, 1896, eighteen months after the accident, when she presented the following condition:—

The position of the wound was marked by a linear cicatrix on the right forearm commencing near the middle line in front, 2.5 centims. above the wrist, and extending inwards to the ulnar side, curving upwards in its course. The cicatrix was not tender, but when firmly pressed, a tingling sensation was sent up the arm and down into the hand. The little and ring fingers were over-extended at the metacarpophalangeal joints, and semi-flexed at the first and second interphalangeal joints. Both fingers were smooth and glossy, the ring finger showing these characters more so on its inner side. The inner half or three-quarters of the palm had a similar shining appearance, and the flexures had almost disappeared. The nail of the little finger was rough and irregularly grown. The joints of the two affected fingers were stiff, and allowed only a limited range of movement either voluntary or passive. The two inner fingers could not be brought into contact with the palm, when she attempted to firmly close the hand. There was both on the little finger and inside of the ring finger, and on the inner half of the palm some slight sensation, but it was of an abnormal character. When touched these parts could be obtusely distinguished, but when pricked with a pin there was no sense of pain. The other parts of the hand were normal.

On 24th January, 1896, the ulnar nerve was laid bare by an incision extending upwards from the pisiform bone about 7 centims. The tendon of the flexor carpi ulnaris was found lying un-united, having been divided at the time of the accident along with the nerve. Both the central and peripheral segments of the ulnar nerve were abnormally thick. The proximal segment of the nerve ended in a hard bulb, about the size of a small hazel nut, which was adherent to the tissue around. This bulb terminated in a tapering strand of tissue, which, however, had no apparent connexion

with the distal segment of the nerve. The peripheral segment of the nerve extended upwards behind the central bulb for a short distance, and was very firmly bound down to the deeper tissues by cicatricial bands. There was no bulb upon this, but it presented a conical ending, terminating also in a strand of tissue, which had no apparent connexion with the central segment. The bulb was cut off from the central segment, and about 4 millims., including the conical ending, removed from the peripheral segment, and in both cases the exposed sections displayed the appearance of nerve tissue. The nerve was then sutured with chromic catgut, passed through the whole thickness, and, after the tendon of the flexor carpi ulnaris had been repaired, the wound was closed, no drainage being used. The arm was bandaged to a splint, with the hand fully flexed.

Three days after the operation there was distinct sense of touch on the inside of the ring finger, but none, not even the obtuse sensation present before the operation, on the little finger. Five days after the operation the patient cried out when the inside of the ring finger, or either the back or front of the little finger, was pricked with a pin, although her head was covered, and she was unaware of what was being done. On the eighth day the wound was dressed, and found healed, and it was found that the senses of touch and pain over the affected area were good, except at the tip of the little finger, where sensation was not distinct. On the twelfth day the sensation was again tested, and it was found that all parts touched with the point of a pin were correctly localised, except over the tip of the little finger. Though felt, sensation was not so distinct as in the normal hand. She cried out when pricked with a pin in any part of the affected area, except over the tip of the little finger. The stitches were removed from the cutaneous wound, and on pressure over it the abnormal sensation formerly felt had disappeared, and the flexor carpi ulnaris was felt as a tense cord. The flexion of the hand had been by this time gradually relaxed, and the arm was put on a splint, with the hand now extended. Electrical treatment was commenced, and, while the faradic current gave no response, the galvanic current gave contractions on closing, in the small muscles of the little finger, but none could be detected in those of the palm. On the twenty-eighth day the sensation was again compared in the two hands. The patient then stated that she felt touch on the inside of the palm and back of the hand, and on the inside of the ring finger, quite as well as in the corresponding parts of the left hand, but that the sense of touch on the first and second internodes of the little finger, while nearly as distinct, was not quite, while in the terminal phalanx of the little finger gentle touches with the point of a pin were felt, but very indistinctly. When pricked with a pin at any part other than the terminal phalanx of the little finger, pain was the result, but in the latter the sensation was only that of touch. By the beginning of the second month, the nutrition of the ulnar distribution of the hand was showing signs of improvement, and sensation was improved in the terminal phalanx of the little finger, pain being felt on pricking with a pin, as far as 4 millims.

from the tip. The thermic sense was tested and found correct. By six weeks from the date of operation, the last occasion upon which she was seen, the atrophy was less, though still well marked, and, while the sensation remained almost perfect, there was scarcely any improvement in motion. While she registered 22 kilos. on the dynamometer with the left hand, she could only register 4 kilos. with the right.

III.—DEDUCTIONS FROM THE RESULTS OF OPERATION.

Cases of secondary suture are much more valuable for the study of certain questions in the regeneration of nerves, than are cases of primary suture. In the former, if the interval of time elapsed from the time of section till the operation undertaken for repair, is sufficient to allow a condition of stable equilibrium of the parts to be attained, the deductions drawn from the results of operation are much less open to dispute. I have shown in the first part of this paper, that theories have been put forward to account for the early return of sensation after nerve suture, without admitting the restoration of conductivity of the nerve, and the question to be decided in the cases just described, is whether the return of function established, is due to a true reunion of the nerve, or if it can be explained in any other way. I would refer especially to the condition of sensation before and after operation. In the first three cases, before operation, it was carefully determined that sensation was totally lost in the regions of the skin supplied by the injured nerves, this loss including not only the sense of pain, but also that of touch. In the fourth case it was also determined that the sense of pain was absolutely lost in the region supplied by the ulnar nerve, but that there was an obtuse sense of touch present on the little and inside of the ring fingers, sufficient to enable the patient to know when her finger was touched. I take this to be the mediate sensibility, described by LÉTIÉVANT (82), as sensation produced by the impact against the anæsthetic region, being communicated to neighbouring sound papillæ, and thus conveyed along other nerves, without any direct nerve communication existing between the part touched and the nerve conducting the impulse. Thus the impulse produced by touch might in this case have been conducted along the median or radial nerves, and learned from experience by the patient to be, from its obscure character, referred to the anæsthetic area. The absence of the sense of pain pointed to the conclusion, that the ulnar nerve was not conducting, a conclusion which was justified at the operation, as the nerve was found completely divided, and the ends lying apart. Leaving out of account the case in which the nerves were compressed at the seat of fracture, these observations were made at three, six-and-a-half, and eighteen months respectively, from the time of injury, and after the operation the sense of pain made its appearance, in one at the end of two days, in one at the end of three days, and in one at the end of five days. I have already quoted some of the published cases with similar results, and shown that none of the theories which have been advanced to account for early return of

sensation by channels other than that of the injured nerve, are applicable to such as these. The finer anastomoses described by ARLOING and TRIPIER (70), or coarser anastomoses, cannot have existed in these cases, as the sense of pain was totally lost; and the delay between the division of the nerve and the operation, without any return of sensation, shows that no replacement, either by outgrowth from neighbouring nerves as supported by TILLMANN (123), or by development of fine collateral anastomoses as held by REMAK (87), could have taken place. The speedy return of sensation after the operation, therefore, leaves only the conclusion that the return was the result of restoration of conductivity in the injured nerve. In making the tests for returning sensation, the sense of pain was always taken by means of pricking the skin with a pin, in order to avoid the possibility of mistaking mediate for immediate sensibility; for by mediate sensibility only touch is appreciated, and pricking the skin with a pin, if felt, would only be as tactile sensation.

From the time of the first appearance of the sense of pain, sensation gradually improved in the further course of the cases; but the cases showed differences in progress. At first localisation of sensation was imperfect, but this very soon was developed, and in about a month from the time of operation, in two of the cases, the gentlest touches were distinctly felt and correctly localised. In one of the cases the tip of the forefinger, and in another the tip of the little finger, were particularly long in developing sensation. In the case in which the nerves were interrupted at the seat of fracture, the return of sensation was less satisfactory, and it was not till the eighth day that the sense of pain appeared in the palm, and not till six weeks that it commenced to return in the fingers. This delay must be explained by the different nature of the lesion in this case from that in the other cases. In the latter the injury to the nerve was merely division, while in the former an indefinite length of nerve was injured by the pressure of cicatricial tissue; and although portions were removed which seemed to be most involved, doubtless there were portions at a lower level left, which were also much damaged by the pressure. The return of sensation in the ulnar distribution in the first case is particularly remarkable; for in that case the divided ends of the ulnar nerve could not be brought together nearer than about 6 millims.; and yet in the little finger the sense of pain was developed in three days. It must, therefore, be supposed either that the interval between the nerve ends was bridged over in that time by a substance capable of conducting, or that by anastomotic fibres the impulses were conducted along the median nerve in which the ends had been brought into apposition; but from the speed with which sensation in the little finger became perfected, it is more likely that the first view is correct.

In no case did improvement occur in the muscles until a comparatively late period, and as far as I was able to trace the cases, this function only approached a perfect recovery in one case (Case II), and even in that case at the end of a year it was still improving. This delay in the return of motion is an almost generally observed occurrence, and some authors, explaining away the return of sensation, take only

return of motion as a proof of the restoration of the conductivity of the nerve. But the delay in the return of the motor function is easily intelligible when it is remembered that for the recovery of motion, not only the nerve, but also the muscle must undergo repair; while for sensation, only the recovery of the nerve with its end organs is necessary. The injury to the muscle is not only the result of its long inactivity, but also of its long separation from its trophic centres. Thus it is that in all the cases, even the third case, where the separation from the centres must have been less than two months, the muscles affected showed great atrophy, and tested electrically, gave the reaction of degeneration. Supposing, then, their nerve supply to be restored at the time of the first appearance of sensation, the muscles only then would begin to recover, and, in their weakened condition, their recovery must necessarily be a very slow process; and indeed, it is intelligible that in some cases the muscles would be incapable of repair from their complete degeneration. The gradual improvement in the first case was demonstrated by the return of faradic irritability in the small muscles of the thumb, one and a half months after the operation. The return of motion is also hindered by stiffness in the joints; for, in one of the cases, although at the end of a year all atrophy had disappeared, and opposition of the thumb to the tip of the little finger, and abduction of the thumb were easily performed, and although the strength of grip as tested by the hand dynamometer, was almost as good as that of the sound hand, yet the stiffness of the terminal joints of the index and middle fingers interfered with the strength of grip for smaller objects, as it was impossible to bring the tips of these fingers into the centre of the palm. (Plate 5, figs. 1 and 2.)

The operation in none of the cases gave rise to any untoward symptom. Temperature remained normal throughout, and the wounds healed by first intention. In the second case, however, after the wound had apparently healed by first intention, a small pustule formed, and pointed in the line of incision. On opening it, the sutures which had been employed for the nerve came away, and the wound then speedily healed.

The condition of the nerves found when exposed for suture was not the same in every case. In every case the nerves appeared thickened as far up and down as they were exposed, and this was not only exhibited in the central segment, but also in the peripheral. The usual description of the peripheral segment which has been some time separated from the central, is that it is found atrophied, but I did not find this in any case. On the contrary, when the nerve had been sutured, it appeared as a cord of uniform thickness above and below the seat of the suture. The divided ends of the nerves were found in one of two conditions. In two of the nerves they were united by a bulky cicatricial mass, while in two they were lying apart without any apparent connexion one with the other. Where the nerve ends were united this union was evidently not such as to enable function to be carried on. Where the ends were lying apart the central end in both cases presented a bulb of hard consistence,

in one case ending in a tapering filament; while the peripheral end presented in the one case a small hard bulb, and in the other a conical ending. What may have had something to do with the different character of the two peripheral ends, is the fact that the end with the bulb was lying free in loose connective tissue, while the end with the cone was lying firmly bound down to the underlying structures by means of cicatricial bands. The prevailing opinion is that it is useless to do more than raw the peripheral end before suturing, but I always cut off the terminal portions, and the sections exposed always showed an appearance resembling the section of a nerve.

IV.—MICROSCOPICAL EXAMINATION OF THE PORTIONS REMOVED PREVIOUS TO SUTURE.

1. *Methods.*

In every case the portions removed were immediately put into MÜLLER'S fluid, in which they remained for several weeks, the fluid being changed at intervals. After dehydration they were imbedded in paraffin, and both longitudinal and transverse sections prepared with the Cambridge microtome, the sections being cut as thin as possible. The sections were then fixed by the albumen method on slides in series, and stained by various methods. The methods which I found to give the most useful results were the first method of WEIGERT,* and the anilin-blue method of STROEBE (158). I found it useful after staining by WEIGERT'S method to stain the preparation first with safranin and then with eosin, as by that addition the distribution of the nuclei and of the connective tissue was very clearly demonstrated.

2. *Microscopical Appearances.*

THE following Table shows the portions examined.

Part examined.	Nerve.	Case.	Time between injury and excision.
Central bulbous end	Ulnar	I.	6½ months
Peripheral bulbous end	"	IV.	18 months
Peripheral conical end	"	I.	6½ months
Cicatricial intercalary segment . . .	Median	IV.	18 months
" " " "	"	I.	6½ months
Portion compressed at seat of fracture	"	II.	3 months
" " " "	Musculo-spiral with radial and posterior interosseous	III.	} Uncertain Not less than four weeks
" " " "		III.	

* *Vide* LEE, 'The Microtome's Vade-mecum,' Lond., 1893, 3rd edition, p. 362.

a. Central Ends.—The bulbs from the central segments were both very dense with smooth surfaces. One lay surrounded by loose connective tissue, while the other was adherent at its lower end to surrounding cicatricial tissue. The latter had a terminal filament, but with that exception their appearance was similar. The following are the microscopical characters of that from the ulnar of Case I. :—

Under a low power, a longitudinal section shows the nerve entering the bulb at the side. The individual fasciculi bend round in entering the bulb, and when they have entered, the fibres diverge, and spread in different directions throughout the bulb, the fasciculi presenting thus at their entrance a fan shape. The bulb itself has a clearly demarcated outline of connective tissue, but its interior presents a heterogeneous aspect. In a common ground of connective tissue, there is everywhere thickly scattered small bundles of nerve elements. These bundles are cut in all directions, some transversely, appearing as small round points, others longitudinally, appearing as lines which frequently bifurcate, and others in all degrees of obliquity. Here and there multitudes of transversely-cut bundles are grouped together in islets, surrounded by longitudinally-cut bundles.

Under a high power (Plate 7, figs. 1, 3, 5), the upper part of the entering fasciculi shows chiefly normal nerve fibres, but the lower part, while showing occasionally a normal nerve fibre, is made up of a mass of delicate bands. While the old fibres measure in diameter about 9μ , the bands measure only about 3μ in diameter. They have attached to their sides numerous nuclei, the length of which is from five to eight times their breadth, the more elongated measuring 13μ in length, and 1.6μ in breadth. These bands have a granular appearance, and there is little doubt of their being young nerve fibres, seeing that in the centre of many, a delicate thread, the axis-cylinder, can be clearly distinguished. In many also WEIGERT'S method brings out a delicate myeline sheath, appearing as closely-set, bluish-black granules. In the fasciculi which enter the bulb, these new-formed fibres lie in bundles, separated by a few connective tissue fibres, running parallel with the nerve fibres. In the region of transition between the old fibres and the new (Plate 7, fig. 5), an actual connexion between the axis-cylinders of the old and those of the new cannot be traced. What, however, is clear, is that each bundle of new fibres corresponds to a single old fibre, and in many cases the old fibre can be seen tapering off, its place being taken by the new fibres, the number of new fibres becoming greater as the old fibre diminishes, until finally only new fibres remain. In tracing further downwards the groups of new fibres, the number contained in a single bundle increases, and, while the bundle is thereby increased in diameter, the fibres themselves retain a fairly uniform breadth.

Passing into the bulb, there are here no old fibres to be found, but the whole structure is made up of bundles of new fibres, cut in every direction, and surrounded by a small amount of fibrous tissue. The bundles cut transversely are small in diameter (Plate 7, figs. 1 and 3), yet the larger contain an enormous number of

young nerve fibres. These fibres appear as clearly defined circles, containing each in its centre a distinct axis-cylinder. The more prominent have a diameter of 3μ , but there are some which have not more than half that diameter. Many have attached to their sides a nucleus, which here has a circular outline, but which, when compared with those in a longitudinally-cut bundle, is seen to be a section of a spindle-shaped nucleus. The whole bundle is surrounded by a layer of connective tissue, but there is no sheath proper. The fibres which show longitudinally, present the same characters as the new fibres in the entering nerve already described.

Transverse sections of the upper part of the entering nerve in the central bulb of Case IV., show that at this point the nerve has retained its normal arrangement of fasciculi. While some of these fasciculi have retained at this level their normal fibres, others have no old fibres, but instead, groups of young fibres (Plate 8, fig. 1). These young fibres present characters identical with those of the fibres in the bulb already described, but, as a rule, only from three or four up to a dozen are grouped together in a single bundle. These bundles resemble very closely, both in number and in disposition, the arrangement of the single old fibres in neighbouring fasciculi in which the latter have been retained. Around these fasciculi the perineurium and epineurium present normal characters, and the endoneurium appears also to be normal.

The examination of the filament in which the bulb terminated, was made by serial transverse sections. It is composed almost entirely of connective tissue, but at its upper end there are about twenty or thirty small bundles of new nerve fibres. Proportionately as the sections are taken from lower levels, the number of nerve fibres diminishes, and the last section examined, still some distance from the termination of the filament, contains only three small bundles, each containing three or four young nerve fibres.

b. Peripheral Ends.—The bulbous end, removed from the peripheral segment of the ulnar in Case I., was about half the size of that removed from the central end, and had also a firm consistence.

Under a low power, it presents a ground-work of connective tissue, in which lies tissue stained bluish-black by WEIGERT'S method. This tissue runs in bundles, longitudinally from the point at which the bulb was removed, towards the free end. About the middle of the bulb, the more regular longitudinal course of these dark stained bundles ceases, and the remainder of the section is occupied by the same tissue, cut transversely and in various degrees of obliquity, showing thus many circular bundles, isolated or in groups, with a few bundles running longitudinally for a short distance among them.

Examined with a high power, the sections show no old nerve fibres, but the tissue stained by WEIGERT'S method is identical in characters with the new nerve tissue seen in the central bulb. In the distal half of the bulb, the fibres run chiefly longitudinally, and are grouped into bundles, each of which contains many nerve

fibres. These young fibres have the same characters as those in the central bulb. Thus they have the same average diameter, have attached to their sides at very short intervals, elongated nuclei, and have in many cases a delicate myeline sheath. In many, a distinct axis-cylinder is visible, occupying the centre of the fibre. The bundles are separated by fibrous tissue in greater or smaller amount, and in this tissue are a number of round cells with granular contents. A few bundles appear cut transversely, beside those cut longitudinally. In the proximal half of the bulb it is rare to get the fibres running for any great distance in one plane. Thus the majority appear cut transversely or obliquely. The connective tissue here is in larger quantity than at the attached end of the bulb. The bundles of nerve fibres cut transversely are of different size, but, irrespectively of that difference, the contents are identical. They contain (Plate 7, figs. 2 and 4) from a few up to twenty or thirty closely aggregated young nerve fibres. The larger of these measure in diameter 3μ , have a well-defined circular outline, and contain each in its centre a distinct point, the axis-cylinder. There are also many much smaller fibres with similar characters. The bundles also contain the sections of nuclei, the larger of which are about one half the diameter of the larger fibres. Around the bundles, one or two layers of connective tissue are arranged concentrically, but there is no definite sheath.

The conical portion removed from the peripheral segment in Case IV., also contains no old nerve fibres. It has a very dense structure, the nerve elements and connective tissue being very closely aggregated together. A few transverse sections removed from the base of the cone, show the majority of the new fibres in bundles cut transversely (Plate 8, fig. 2), but even at that level a few are cut longitudinally and obliquely. Similarly, in longitudinal sections of the cone, there is no part in which the bundles run exclusively in one direction. Towards the apex of the cone the number of fibres diminishes, and the section appears entirely composed, ultimately, of connective tissue. The characters of the fibres here are identical with those of the fibres already described, but a few show the formation of the myeline sheath more distinctly than those either in the peripheral or central bulbs of Case I. In some of the fibres, it has taken on the stain so deeply that the contents of the fibre are quite hidden, and it appears as a uniform granular coat.

The cone terminated in a filament about 12 millims. in length, and this was examined for nerve fibres by serial transverse sections, but none were found. The core of the filament is occupied by a blood vessel, and the remainder is simply connective tissue.

c. Intercalary Cicatricial Segments.—The cicatricial mass which united the two ends of the median in Case I., measured 1.5 centim. in length and 1 centim. in breadth. It had a rough and somewhat irregular surface and firm consistence. It was thicker in the middle, and narrowed to the thickness of the nerve at either end.

Transverse sections from its proximal end (Plate 8, fig. 3) show a network of

dense fibrous tissue, containing in its meshes bundles of nerve elements. In some parts the connective tissue fibres run longitudinally, appearing as points in section, but in others they run transversely, being there displayed in a large part of their course in the section. The bundles of nerve elements are uniformly distributed throughout the section, but they are small, the larger measuring only 30μ in diameter, and are isolated from each other by a considerable breadth of dense fibrous tissue. Some are very small, containing only two or three fibres, while the larger contain as many as twenty. All the fibres exposed are small new fibres, no old fibres being present. These fibres agree in characters with those already described. They have a very sharply defined outline, the axis-cylinder is very distinct, and there are many nuclei lying between them and attached to their sides. Many of these fibres are larger than any met with in the other cases, some measuring 4μ in diameter.

The distal end of the mass presents a less regular aspect. In some parts (Plate 8, fig. 4) there are dense masses of fibrous tissue, and only isolated bundles of nerve elements, grouped together, while in other parts (Plate 9, fig. 1), the distribution of the nerve elements is very uniform. These uniformly distributed bundles are still smaller than the bundles in the proximal end, the largest measuring 17μ in diameter, but the majority much smaller. The larger contain eight or ten young fibres, and the smaller from two to three or four. In addition to these, there are many isolated fibres. The young fibres are the same in structure as those in the opposite end of the mass. The bundles do not all appear in transverse section, but a few appear running longitudinally in the section, and, therefore, transversely in the mass, and a few obliquely cut. In these the spindle-shaped nuclei attached to the sides of the fibres are displayed. Also in many such fibres the axis-cylinders are shown as delicate threads (Plate 8, fig. 4).

The characters of this mass, which have been described from transverse sections from its two opposite ends, are shown by longitudinal sections to be maintained throughout the whole mass. The arrangement of the bundles is very irregular. In the same longitudinal section are to be seen islets of transversely-cut bundles (Plate 8, fig. 5), and coursing around them, bundles cut longitudinally and obliquely. Some of the longitudinally-cut bundles contain fibres which show very well the developing myeline sheath, not, however, sufficiently dense to hide the delicate axis-cylinder (Plate 8, fig. 6).

The intercalary mass from the median of Case III. agrees in characters with that just described so closely that a separate description is unnecessary.

d. Portions Compressed at Seat of Fracture.—The portion excised from the median, and that from the musculo-spiral with its two branches, are examples of nerves which have been under compression for several weeks.

The portion excised from the median measured in length only about 12 millims., yet transverse sections from the proximal and distal ends show very different

structures. The transverse section of the proximal end (Plate 9, fig. 2) is practically that of a normal nerve, showing throughout a normal subdivision into fasciculi, surrounded each by a normal perineurium, and each containing normal myeline fibres, the majority of which measure about 8μ in diameter. The section agrees in every particular with transverse sections of normal human nerves, which were treated by the same methods for comparison. The transverse section of the distal end shows a normal subdivision into fasciculi, and, under a very low power, looks like the section of a normal nerve, with the exception that, treated by WEIGERT'S method, the fasciculi are not stained so deeply. With a high power, however (Plate 9, fig. 3), the difference from the normal nerve is very decided, for the fasciculi contain no old myeline fibres, but in their place groups of young fibres. The perineurium surrounding each of the fasciculi has a normal appearance, but the endoneurial tissue has, if anything, a stronger development than normally. The groups of young fibres are small, the majority measuring about 8μ in diameter, with here and there a few larger examples. As a rule, they contain only three or four young nerve fibres, each presenting a sharp circular outline, and containing an axis-cylinder in its centre, together with one or two nuclei, either lying between the young fibres or at the circumference of the small bundle. Most of the bundles are surrounded by a delicate membrane. All the bundles shown in the section are transversely cut. The epineurium is normal, and no young fibres are found between the layers of the perineurium.

The portion removed from the musculo-spiral nerve and its two branches included the terminal 12 millims. of the former, with 6 millims. of the radial, and 3 millims. of the posterior interosseous. The transverse section of the proximal end of the musculo-spiral is normal, while those of the distal ends of the radial and posterior-interosseous present no old nerve fibres, but instead, groups of young fibres arranged as in the distal end of the portion of the median just described. In the transverse sections which have passed through the region of transition from the old fibres to the new, some of the fasciculi show an arrangement of old myeline fibres which is that of a normal nerve, but many of the myeline fibres have an abnormal character. In the simplest of these, the axis-cylinder is greatly hypertrophied, and the whole fibre is enlarged (Plate 9, fig. 5). In others, between the sheath of SCHWANN and the myeline sheath is a large nucleus, presenting a circular outline. In another, in addition to the large nucleus, and lying alongside of it, are one or two very distinct young nerve fibres with clearly-defined circular outlines, and delicate axis-cylinders, while the myeline sheath of the old fibre is indented by the new-formed structures, and the old sheath of SCHWANN is slightly distended (Plate 9, fig. 5). The old fibre, however, has still its characters preserved. The majority of such old fibres measure about 12μ in diameter, while the new fibres intercalated between the sheath of SCHWANN and the myeline sheath measure 3μ in diameter, and the nucleus has a diameter approximately the same. Other old fibres in the same section present

three, four, and up to a dozen newly-formed fibres lying in the same position, and the number of nuclei present is proportionately increased to two, three, or more. Just as the old fibres present a greater number of young fibres, so the old myeline sheath and axis-cylinder appear crushed to the one side and diminished (Plate 9, figs. 6 and 7). In some, in which the old sheaths of SCHWANN contain about a dozen new fibres, traces of the old axis-cylinder and myeline sheath can still be seen at one side of the group, while, in other cases, no trace of the old myeline sheath and axis-cylinder can be found, and there is merely a group of young fibres with nuclei, surrounded by the old sheath of SCHWANN. Those old fibres, which still contain the myeline sheath and axis-cylinder, and yet have young fibres between the myeline sheath and sheath of SCHWANN, show the latter sheath distended in proportion to the number of young fibres present. Also, where the myeline sheath and axis-cylinder of the old fibres have disappeared, many show the old sheath of SCHWANN surrounding the group of young fibres, but, in some, where the number of young fibres in a bundle is great, the old sheath of SCHWANN is very difficult to trace.

A longitudinal section made through the same region shows the old myeline fibres terminating and giving place to the young fibres (Plate 9, fig. 4); and the sheath, enclosing the bundle of young fibres, can often be traced into continuity with the old sheath of SCHWANN. The more common condition traced from the old fibre above down into the bundle of young fibres is as follows:—The old fibre gradually increases in diameter, and presents finally what approaches a bulbous condition. In its interior the axis-cylinder is swollen and presents in many cases a bulb. Beyond this the old myeline sheath and axis-cylinder contract greatly and terminate almost immediately. The sheath of SCHWANN is continued beyond the bulbous myeline fibre as the sheath surrounding the bundle of young fibres. Often, before the termination of the old fibre is reached, isolated young fibres can be seen, running between the sheath of SCHWANN and the myeline sheath. These pass downwards, until they are lost in the bundle of young fibres beyond the old. The nuclei seen in transverse sections as circular are here shown to be spindle-shaped.

V.—DEDUCTIONS FROM THE MICROSCOPICAL APPEARANCES.

1. *Degeneration.*

The length of time which has elapsed from the time of injury till the examination of the nerve in these cases, precludes the study of the earlier stages of degeneration, but allows certain deductions concerning the later stages and final result of the process.

The sheath of SCHWANN, notwithstanding the lapse of several weeks from the commencement of compression, still remains in the portions of nerve from Case III. (Plate 9, fig. 3). It can be traced downwards from the old fibre into the region of

the new fibres, where, for a time, it is retained (Plate 9, fig. 4). But as the new fibres increase in numbers, the old sheath is gradually distended, and ultimately becomes unrecognisable, probably becoming part of the endoneurial connective tissue. This, then, accords with the view expressed in the recent papers by BÜNGNER (150), HOWELL and HUBER (156), STROEBE (158), and NOTTHAFFT (159), that the sheath of SCHWANN is retained for a time after degeneration of the other parts of the fibre, but that it is destroyed during the regenerative process.

Where the old sheath of SCHWANN is still retained, it contains nothing which could be taken for the old axis-cylinder. The latter, traced into the region of compression, is seen terminating, often in bulbous ends, and below that, the contents of the old sheath are only new-formed elements (Plate 7, fig. 5; Plate 9, fig. 4). In other cases, the gradual disappearance of the old axis-cylinder can be seen in transverse sections through the point of transition from old to new fibres (Plate 9, figs. 5, 6, and 7). In the portions of nerve removed from peripheral segments there are no old fibres to be seen, and no structures which could be taken for old axis-cylinders. My results are, therefore, not in accord with the view taken by SCHIFF (31), PHILIPPEAUX and VULPIAN (39), WOLBERG (127), and others, that both the old sheath of SCHWANN and the old axis-cylinder are retained in the whole peripheral segment. RANVIER (102), also, while he finds that the axis-cylinder is destroyed in the peripheral segment, holds that it is retained in the central, unless exceptionally, and that the degenerative process affects only the extremely small portion of the central segment measured by one or two of the nodes now called by his name. But in the central bulbs examined there are portions of the old nerve, about 6 millims. in length, attached to the side of the bulb, and it is only at the extreme upper part of this that old fibres are present, while the remainder is entirely occupied by new fibres, among which no trace of the old axis-cylinders is visible.

The view taken by KRAUSE (136) that the sensory fibres from the touch corpuscles of WAGNER and MEISSNER, having their nutritive centres there, undergo degeneration in the central segment, while they remain sound in the peripheral segment, has been taken as an explanation of the conflicting results of other authors. KRAUSE found that transverse sections of the central segment showed about one-half of the fibres degenerated, while he merely assumed that in the peripheral segment there were a corresponding proportion of the fibres which remained sound, his assumption being based on analogy with the condition found in rabbits. But in the transverse sections made from the proximal ends of the portions from the median and musculo-spiral nerves of Case III., the appearances presented are those of a normal nerve (Plate 9, fig. 2); in none of the fasciculi are any new fibres found, and there has therefore been no degeneration. Also, in portions removed from peripheral segments, no old fibres are present. I cannot, therefore, agree with KRAUSE that there is an immediate ascending degeneration in the central segment, for the proportion of fibres indicated by him as becoming degenerated in the central segment is so great that there would

be no difficulty in seeing them if present, or the resulting regeneration in any case. This is also the opinion expressed by GOTTSACKER (145) from examination of stump neuromata. From the account given by S. MEYER (100, 108, 125), HAMMER (161), and TEUSCHER (149), it would appear that in any nerve there are always to be found degenerated fibres; but that these are present only very sparingly, and are due to a normal process of degeneration. KRAUSE'S results were obtained from the examination of nerves in limbs amputated for gangrene. Several of these were senile or diabetic gangrene, and it is, therefore, possible that in his cases the degeneration of the nerve was primary to the gangrene. This is more likely, if we are to regard, with S. MEYER, the nerve fibres, not as perennial structures, but as undergoing a normal process of degeneration and regeneration; and this view is supported by the work of KORYBUTT-DASZKIEWICZ (105), who found an active formation of nerve-fibres in the nerves of the frog, on placing the frogs in favourable surroundings, after a period of starvation. In any case, if an immediate ascending degeneration were caused by interruption of the course of a nerve, there would have been some evidence of that in the transverse sections of the proximal ends of the median and musculo-spiral portions from Case III.

2. *Regeneration of nerve fibres in the peripheral segment, while still separated from the central segment.*

The portions of nerves examined show very clearly, not only that in regeneration the young fibres are produced both in the central and in the peripheral segment, but also that reunion of the ends is not an essential to the production of young fibres in the peripheral segment (Plate 7, figs. 2 and 4; Plate 8, fig. 2). This independent origin of new fibres in the peripheral segment, without previous reunion with the central end, first observed and described by PHILIPPEAUX and VULPIAN (38, 39), has been opposed by almost all who have since made a study of regeneration of nerves; and their opinion was also greatly weakened by the fact that VULPIAN (77, 86) himself withdrew from his former position. MITCHELL (80), and recently BOWLBY (146) have found in the examination of portions removed from the peripheral segments of un-united divided nerves, that many newly formed nerve fibres are there present. The opponents of this view give various explanations of the results of these observers. Some hold that PHILIPPEAUX and VULPIAN mistook products of degeneration for young fibres; SCHIFF (41), and AMBROSOLI (43) that their results were only to be got in very young animals; while RANVIER (102), again, thinks that they did observe the peripheral segment regenerated, but that they had failed to observe certain strands of tissue between the central and peripheral ends, through which the peripheral segment had been regenerated. He supports this allegation by an observation of his own, where a central segment lying separate from its peripheral, was connected to it by a membrane having the appearance of connective tissue, but which contained nerve fibres, as shown by the tint which it took on being subjected to the action of

osmic acid. HOWELL and HUBER (156) in opposing the results of BOWLBY, hold that the young fibres which he observed, were simply sections of nuclei, and that the point in their interior, taken for the axis-cylinder, was nothing more than the nucleolus, and state that this explanation is more likely, since BOWLBY figures no nuclei among the bundles of fibres. It is true that in BOWLBY'S figures there are no nuclei shown among the young fibres, and he believes that the axis-cylinders are formed by the nuclei. But in my preparations there can be no doubt of the structures in question being young nerve fibres; for the axis-cylinder shown in transverse section as a point, is clearly visible in many fibres seen longitudinally, as a delicate thread. Also in the bundles which are cut transversely, nuclei are always present (Plate 7, fig. 4), lying between the fibres, and in many cases distinctly attached to the fibres; and in fibres seen longitudinally these nuclei are spindle-shaped, and distinctly attached to the sides of the fibres. The difference between the axis-cylinders and the nuclei of a bundle is well shown in some of the preparations, which were stained by the method recommended by STROEBE; for the former have taken on the aniline blue, while the latter have taken the red colour of the safranin. But that they are really nerve fibres, does not rest alone on the axis-cylinder being demonstrated, for they also in many cases show a commencing myeline sheath. In order to find if they could possibly have been communicated to the peripheral segment from the central end of the nerve through fine bands of tissue connecting the ends as suggested by RANVIER, I made a careful search for such. In one of the cases such were present, in the form of fine filaments, one attached to the central end, and one to the peripheral, but without any connexion one with the other. In that attached to the peripheral, there were no nerve elements present, while in that taken from the central end, the upper portion contained only a few isolated bundles of young nerve fibres, which gradually diminished in numbers, as the sections were taken further away from the bulb, until in the last section taken, still some distance from the termination of the filament, only three small bundles remained. I found, therefore, no means of communication between the ends, and must conclude that the young fibres observed in the peripheral segment have an independent origin there.

VANLAIR (122) found in the sciatic nerve of a dog, that four months after resection of a portion there was reunion of the ends by a cicatricial segment, but no functional return. The cicatricial segment, he found regenerated, but the peripheral segment contained only fibres which he regarded as end products of degeneration, and called "atrophic degeneration." His description of these fibres agrees with the appearance presented by newly-formed fibres, and I think it probable that they were such, and not the products of degeneration.

3. *The Origin of the Young Fibres.*

The arrangement, wherever they are found, of the new fibres in bundles suggests that the fibres composing each bundle have had a common origin. As a rule, the

number contained in a single bundle is great. The part of the nerve in which they originate can be seen, when sections from the central segment close to the termination of the old fibres are examined; for, while the young fibres are there seen still in bundles, these bundles are small, and contain few young fibres. The diameter of these small groups of fibres is approximately the same as that of a single old fibre, and the sheath of SCHWANN can be traced down in longitudinal sections, from the old fibre into the region of the new, where it is seen surrounding the small bundle of new fibres (Plate 9, figs. 3 and 4). It is clear from this that these young fibres originate within the sheath of SCHWANN. On tracing them downwards in longitudinal sections, they are found to increase in numbers and distend the sheath of SCHWANN, which ultimately becomes unrecognisable. It is thus probable that the young fibres of each of the bundles which appear in the central bulb and in the end of the peripheral segment, represent in most cases fibres which have had a common origin from within one old sheath of SCHWANN.

The epineurium and perineurium appear normal in the portion of nerve immediately proximal to the central bulb, and in the portions removed from the seat of compression (Plate 8, fig. 1; Plate 9, fig. 3). There is, therefore, nothing to indicate an origin of nerve fibres from the cells of the perineurium as described by HJELT (44), WOLBERG (127), and HANKEN (143). Also the view of VANLAIR (122) that the new fibres proceed into the perineurium, and out into the epineurium, forming a zone round the fasciculus, has nothing to support it in my preparations.

If, then, the new fibres originate within the old sheath of SCHWANN, they must be formed either by growth from the old fibre above, as described by RANVIER (81, 102) and others; or from the remains of the old fibre, as held by many; or from the protoplasm and nuclei of the sheath of SCHWANN, as held by BÜNGNER (150) and others. The manner in which the old fibre ceases abruptly, and gives place to many young fibres which occupy the continuation of its sheath of SCHWANN, may suggest an origin such as described by RANVIER and others; but the presence of undoubted young nerve fibres in the peripheral segment, while it has no connexion with the central segment, is incompatible with this view. The young fibres also cannot originate from the remains of the old, as in the region of transition from the old to the new, both old fibres and young are seen enclosed within a common sheath of SCHWANN (Plate 9, figs. 5, 6 and 7). Thus the only source left from which to derive the young fibres within the old sheath of SCHWANN, is the nucleus and protoplasm of the interannular segment. This conclusion is strengthened by the examination of transverse sections, passing through the point of transition from the old fibres to the new; for there, the old fibre can be seen with one or more young fibres lying beside the nucleus, and between the sheath of SCHWANN and the myeline sheath (Plate 9, figs. 5 to 7). The enormous number of spindle-shaped nuclei among the nerve fibres, indicates that these structures have originated by proliferation from the nuclei of the sheath of SCHWANN, but in my preparations the

proliferative stage had evidently come to a conclusion, as no indications of karyomitosis were present.

My results are, therefore, in accord with the opinion expressed in BÜNGNER'S recent paper, that the nuclei and protoplasm of the interannular segments must be viewed as neuroblasts, their function being to produce new nerve fibres. And, taking into account the observations of S. MEYER (100, 108, 125), it would appear that the exercise of their function is not reserved for accidents such as nerve section, but occurs normally, the fibres undergoing a normal degeneration and regeneration. The bundles of young fibres were seen by HOWELL and HUBER (156) in the peripheral end of nerves which had not united, but having failed to stain the axis-cylinder they call them "embryonic fibres," and find that they receive axis-cylinders only by growth of the latter from those of the old fibres in the central end. That these fibres observed by HOWELL and HUBER were really nerve fibres, is shown by the fact that when the peripheral segment, containing only such, was mechanically irritated, a low degree of irritability and conductivity was found.

4. *Characters of the Young Fibres.*

The young fibres appear with a central axis-cylinder, with a protoplasmic surrounding zone, having a well-defined outline, and with spindle-shaped nuclei attached at short intervals to their sides. It is evident, therefore, that the nuclei do not form the axis-cylinder as described by BOWLBY (146), but that in the formation of the fibre only the central portion of the primitive protoplasmic thread becomes developed into the axis-cylinder. In many fibres, both in the central and peripheral ends, the protoplasmic zone contains a granular deposit which takes on the characteristic tint of myeline by treatment with WEIGERT'S method (Plate 8, fig. 6). It is, therefore, clear that the myeline sheath is deposited in the protoplasm gradually and uniformly. In transverse section the young fibres correspond in appearance and in diameter (3μ) with the "fibres à gaine vitreuse" of VANLAIR (122), and according to him the "gaine vitreuse" is a provisional covering of the axis-cylinder, derived from the connective tissue around, which becomes thinner as the normal sheaths of the axis-cylinder develop, and finally becomes the fibrillar sheath. I think it more probable that the zone surrounding the axis-cylinder is the protoplasmic residue not used up in the formation of that structure, and that after the myeline sheath becomes deposited within it, it remains with the nucleus as the protoplasm of the interannular segment.

Independently of the time which has elapsed from the injury till the excision of the portions of nerve examined, the stage of development of the young fibres is the same, with the exception that some show more distinctly than others the commencing myeline sheath; and this similarity occurs both in the central and peripheral ends. As this time varied from a few weeks to eighteen months, the development presented

by the fibres must be regarded as a resting stage. It is probable that the further steps in development to the adult fibre depend on a restoration of continuity of the nerve, and that such as would allow the transmission of impulses through the young fibres. Also the observation of PHILIPPEAUX and VULPIAN (39) that regeneration is more rapid when union is effected, may be explained on the view that reunion is necessary to the further development of the fibres. That these young fibres are capable of transmitting impulses, I take the observations of HOWELL and HUBER as proving; and this explains also why, after the operation of suture, so rapid a return of sensation in the parts previously anæsthetic occurs.

With regard to the formation of the new sheath of SCHWANN, it might be viewed as a metamorphosed outer layer of the young fibre, but this is unlikely from the behaviour of the old sheath. For, since that structure does not degenerate along with the rest of the fibre, and is only finally destroyed or displaced by the mechanical condition that it is no longer able to contain the developing fibres, it does not act as part of the fibre. It is more probable that it is an addition to the fibre from the surrounding connective tissue.

On comparing the transverse section of a nerve made through a part which contains the old fibres, with one made further down in the region containing new fibres, the increase in numbers of the new fibres as compared with the old is very striking. It is seen that the number of groups of the new fibres is approximately equal to the number of old fibres, and as each group contains at a high level three or four, and at a lower many more, the numerical increase may be roughly estimated (Plate 9, figs. 2 and 3). It is hardly likely that all such fibres are developed to the stage of maturity. It may be that when reunion is established, only the normal number of fibres develop further, while the others perish or remain undeveloped; but this is a subject upon which there is as yet no evidence.

5. *Cicatricial Intercalary Segments.*

The nature of the cicatricial mass, uniting two ends of a nerve by a bond which does not allow re-establishment of function, is illustrated by two of the cases. In these, although the mass has the appearance of cicatricial connective tissue, yet the microscopical examination shows that from end to end the mass contains a rich supply of young nerve fibres. But at the same time, these young fibres are separated by much dense connective tissue, which in some places is massed together to the exclusion of young nerve fibres (Plate 5, figs. 3 to 6; Plate 6, fig. 1). This mass has evidently been supplied with nerve fibres by immigration into it of neuroblasts, either from the central end or from both. I think from both ends, from the fact that both central and peripheral ends of nerves, remaining entirely separated, show at their ends a mass of connective tissue containing nerve fibres. The latter do not run in parallel lines, as they do when met in a piece of old nerve,

but are convoluted, showing that they have been developed in the irregular spaces of the connective tissue. But if a cicatricial mass connecting the two ends of a divided nerve is thus supplied with nerve fibres from the central and peripheral ends, there must be some cause preventing the transmission of impulses. The explanation which seems to me most probable, is that if there has been much inflammation in the parts, the amount of cicatricial tissue in the mass is so great, that by the time the mass is bridged over by nerve fibres, the contraction of the cicatricial tissue has become so great, that the nerve fibres are prevented from transmitting impulses or developing further, in a way exactly analogous to that which occurs when a nerve is involved in the callus of a fracture.

VI.—GENERAL CONCLUSIONS.

1st. Un-united divided nerves, sutured long after division, can re-unite and transmit impulses in a few days.

2nd. After division or interruption of a nerve, there is no ascending degeneration of the kind described by KRAUSE.

3rd. The old axis-cylinder is destroyed in the peripheral segment, and in the ultimate portion of the central segment.

4th. New fibres originate in the peripheral segment as well as in the central end.

5th. The formation of new fibres in the peripheral segment occurs, although there is no connection with the central end, but maturation of the fibre is not completed while separation of the ends lasts.

6th. The new fibres originate from cells within the sheath of SCHWANN.

7th. In the development of the young fibres, the central portion of the primitive protoplasmic thread forms an axis-cylinder, and the myeline sheath is deposited in the surrounding protoplasmic zone, which latter remains along with the nucleus as the neuroblastic element of the interannular segment.

8th. The cicatricial mass uniting the ends of a divided nerve may be permeated by young nerve fibres from end to end without functional union being effected, if the amount of cicatricial connective tissue present in the mass is sufficient by its pressure to prevent the passage of impulses.

BIBLIOGRAPHY.

[The original source is placed in brackets in those cases in which abstracts only were read.]

1. GUIDO DE CAULIACO. *Chirurgia*. Lugd., 1537, p. 114.
2. CRUIKSHANK, WM. Experiments on the Nerves, particularly on their Reproduction; and on the Spinal Marrow of Living Animals. *Phil. Trans.*, 1795, I., p. 177.

3. FONTANA. *Traité sur le venin de la vipère, &c.* Florence, 1781, vol. 2, p. 177.
4. MONRO, ALEX. *Observations on the Structure and Functions of the Nervous System.* Edin., 1783, p. 81.
5. ARNEMANN, JUSTUS. *Versuche über die Regeneration an lebenden Thieren.* Göttingen, 1787.
6. HAIGHTON, JOHN. *An Experimental Inquiry concerning the Reproduction of Nerves.* *Phil. Trans.*, 1795, I., p. 190.
7. MEYER, J. C. H. *Ueber die Wiedererzeugung der Nerven.* *REIL'S Archiv f. d. Physiol.*, vol. 2, 1797, p. 449.
8. MAGENDIE. *Expériences et Remarques &c.* *Journ. de Physiol. Expériment.*, 1821, vol. 1, No. 2, p. 120.
9. FLOURENS. [*Expériences sur le système nerveux.* Paris, 1825, p. 18; *Annales des Scienc. Natur.*, 1827, p. 439.] *SCHMIDT'S Jahrbücher*, vol. 5, 1835, p. 94.
10. PRÉVOST. *Ueber die Wiedererzeugung des Nervengewebes.* *FRORIEP'S Notizen*, vol. 17, No. 360, 1827, p. 113.
11. TIEDEMANN. *Nervendurchschneidung und Regeneration.* [*TREVIRANUS, Zeitschr. f. Physiol.*, 1831, vol. 4, p. 68.] *SCHMIDT'S Jahrbücher*, vol. 5, 1835, p. 95.
12. FRIEDREICH, J. B. *Die neusten Erfahrungen und Ansichten über die Localkrankheiten, und die Wiedererzeugung der Nerven, mit Berücksichtigung der Literatur.* *SCHMIDT'S Jahrbücher*, vol. 5, 1835, p. 89.
13. HAMILTON. *On some Effects resulting from Wounds of Nerves.* *Dublin Journ. of Med. Science*, vol. 13, 1838, p. 38.
14. STEINRÜCK, OTTO. [*De nervorum regeneratione commentatio physiologica.* Berolini, 1838.] *SCHMIDT'S Jahrbücher*, vol. 26, 1840, p. 102.
15. NASSE. *Ueber die Veränderungen der Nervenfasern nach ihrer Durchschneidung.* *MÜLLER'S Archiv*, 1839, p. 405.
16. GÜNTHER und SCHÖN. *Versuche und Bemerkungen über Regeneration der Nerven, und Abhängigkeit der peripherischen Nerven von den Centralorganen.* *MÜLLER'S Archiv*, 1840, p. 270.
17. BIDDER, F. *Versuche über die Möglichkeit des Zusammenheilens functionell verschiedener Nervenfasern.* *MÜLLER'S Archiv*, 1842, p. 102.
18. STANNIUS. *Untersuchungen über Muskelreizbarkeit.* *MÜLLER'S Archiv*, 1847, p. 443.
19. BROWN-SÉQUARD. *Sur les altérations pathologiques, qui suivent la section du nerf sciatique.* *Compt. Rend. de la Société de Biologie.*, 1849, p. 136.
20. WALLER, A. *Experiments on the Section of the Glossopharyngeal and Hypoglossal Nerves of the Frog, and Observations of the Alterations produced thereby in the Structure of their Primitive Fibres.* *Phil. Trans.*, 1850, II., p. 423.
21. BUDGE. *Neurologische Mittheilungen.* *Zeitsch. f. Wissensch. Zool.*, vol. 3, 1851, p. 347.

22. WALLER, A. Nouvelle méthode pour l'étude du système nerveux &c. *Compt. Rend. de l'Acad.*, vol. 33, 1851, p. 606.
23. — Sur la reproduction des nerfs, et sur la structure et les fonctions des ganglions spinaux. *MÜLLER'S Archiv*, 1852, p. 392.
24. — A New Method for the Study of the Nervous System. *Lond. Journ. of Med.*, vol. 4, 1852, p. 609.
25. — Recherches expérimentales sur la structure et les fonctions des ganglions. *Compt. Rend. de l'Acad.*, vol. 34, 1852, p. 524.
26. — Observations sur les effets de la section des racines spinales et du nerf pneumogastrique au-dessus de son ganglion inférieur chez les Mammifères. *Compt. Rend. de l'Acad.*, vol. 34, 1852, p. 582.
27. — Nouvelles recherches sur la régénération des fibres nerveuses. *Comp. Rend. de l'Acad.*, vol. 34, 1852, p. 675.
28. — Examen des altérations qui ont lieu dans les filets d'origine du nerf pneumogastrique et des nerfs rachidiens, par suite de la section de ces nerfs au-dessus de leur ganglions. *Compt. Rend. de l'Acad.*, vol. 34, 1852, p. 842.
29. — Sixième Mémoire sur le système nerveux. *Compt. Rend. de l'Acad.*, vol. 34, 1852, p. 979.
30. PAGET, JAMES. *Lectures on Surgical Pathology*. London, 1853, vol. 1, p. 282.
31. SCHIFF. Sur la régénération des nerfs et sur les altérations qui surviennent dans les nerfs paralysés. *Compt. Rend. de l'Acad.*, vol. 38, 1854, p. 448.
32. BRUCH. Ueber die Regeneration durchschnittener Nerven (Vorläufige Mittheilung). *Zeitschr. f. Wissensch. Zool.*, vol. 6, 1855, p. 135.
33. HUTIN, FELIX. Anatomie pathologique des Cicatrices dans les différents tissus. *Mémoires de l'Acad. Impér. de Méd.*, vol. 19, 1855, p. 467.
34. LENT, ED. Beiträge zur Lehre von der Regeneration durchschnittener Nerven. *Zeitschr. f. Wissensch. Zool.*, vol. 7, 1856, p. 145.
35. SCHIFF. Ueber die Degeneration und Regeneration der Nerven mit besonderer Beziehung auf die Mittheilungen von EDUARD LENT. *Zeitschr. f. Wissensch. Zool.*, vol. 7, 1856, p. 338.
36. BERNARD, CLAUDE. Leçons sur la physiologie et la pathologie du Système Nerveux. Paris, 1858, vol. 1, Leç. 2 and 3.
37. GLUGE et THIERNESSE. Sur la réunion des fibres nerveuses sensibles avec les fibres motrices. *Journ. de la Physiol., BROWN-SÉQUARD*, vol. 2, 1859, p. 686.
38. PHILIPPEAUX et VULPIAN. Note sur des expériences démontrant que des nerfs séparés des centres nerveux peuvent, après s'être altérés complètement, se régénérer tout en demeurant isolés de ces centres, et recouvrer leur propriétés physiologiques. *Compt. Rend. de l'Acad.*, vol. 49, 1859, p. 507. Reprint in *Journ. de la Physiol., BROWN-SÉQUARD*, vol. 3, 1860, p. 214.
39. — Recherches expérimentales sur la régénération des nerfs séparés des centres

- nerveux ; communiquées à la Société de Biologie pendant l'année 1859. Gazette Méd. de Paris, vol. 15, 1860, pp. 420, 446, 460, 476, 495, 526, 538, 575, 602.
40. BROWN-SÉQUARD. Sur l'indépendance des propriétés vitales des nerfs moteurs. Journ. de la Physiol., BROWN-SÉQUARD, vol. 3, 1860, p. 160.
 41. SCHIFF. Remarques sur les expériences de MM. PHILIPPEAUX et VULPIAN, sur la régénération des nerfs. Journ. de la Physiol., BROWN-SÉQUARD, vol. 3, 1860, p. 217.
 42. LANDRY. Réflexions sur les expériences de MM. PHILIPPEAUX et VULPIAN relatives à la régénération des nerfs. Journ. de la Physiol., BROWN-SÉQUARD, vol. 3, 1860, p. 218.
 43. AMBROSOLI, C. Ueber die Verbindung der sensibeln und motorischen Nervenfasern. [Presse Méd. 32, 1860.] SCHMIDT'S Jahrbücher, vol. 108, 1860, p. 289.
 44. HJELT, OTTO. Ueber die Regeneration der Nerven. VIRCHOW'S Archiv, vol. 19, 1860, p. 352.
 45. PHILIPPEAUX et VULPIAN. Compt. Rend. de l'Acad., vol. 51, 1860, p. 363.
 46. WALTER, GEORG. Ueber die fettige Degeneration der Nerven nach ihrer Durchschneidung. VIRCHOW'S Archiv, vol. 20, 1861, p. 426.
 47. PHILIPPEAUX et VULPIAN. Note sur la régénération des nerfs transplantés. Compt. Rend. de l'Acad., vol. 52, 1861, p. 849.
 48. CORNIL. De la régénération des nerfs. Archives Générales de Médecine, 5th Series, vol. 19, 1862, p. 81.
 49. REMAK. Ueber die Wiedererzeugung von Nervenfasern. VIRCHOW'S Archiv, vol. 23, 1862, p. 441.
 50. HUTCHINSON. Case illustrating the Influence of the Nerves upon Nutrition and Animal Heat. Med. Times and Gazette, 1862, vol. 2, p. 196.
 51. VIRCHOW. Die krankhaften Geschwülste. Berlin, 1863, vol. 3, Hälfte 1, Neurome, p. 233.
 52. GLUGE et THIERNESSE. Expériences sur la réunion des nerfs sensibles et des nerfs moteurs. Gazette Hebdomadaire, 1864, No. 25, p. 423.
 53. SCHUH. Mittheilungen über Resektionen und andere Operationen an Nerven. [Wien. Med. Wochen., 13, 1863.] SCHMIDT'S Jahrbücher, vol. 122, 1864, p. 217.
 54. HOUEL. Gazette des Hôpitaux, 1864, No. 77, p. 307, "Société de Chirurgie."
 55. LAUGIER. Compt. Rend. de l'Acad., vol. 58, 1864, p. 1139.
 56. EULENBURG und LANDOIS. Die Nerven-Naht. Berl. Klin. Wochenschr, 1864, I., No. 46, 47.
 57. GUÉRIN, J. Réunion des nerfs divisés, rétablissement immédiat de la fonction. Gaz. Méd de Paris, 19, 1864, p. 415.
 58. LEUDET et DELABOST. Note sur un cas de division ancienne d'une partie des

- nerfs avec rétablissement incomplet de la sensibilité. *Gaz. Méd. de Paris*, 19, 1864, p. 148.
59. BIDDER, F. Erfolge von Nervendurchschneidung an einem Frosch. *Archiv f. Anat. u. Physiol.*, 1865, p. 67.
60. EULENBURG UND LANDOIS. [Berl. Kl. Wochenschr., II., 10, 1865.] SCHMIDT'S Jahrbücher, 1865, vol. 128, p. 320.
61. MAGNIEN. Recherches expérimentales sur les effets consécutifs à la section des nerfs mixtes. [Thèse, Paris, 1866.] VIRCHOW-HIRSCH, Jahresbericht, 1866, vol. 1, p. 115.
62. RICHEL. Section du nerf médian. Conservation de la sensibilité tégumentaire. Sensibilité récurrente exceptionnelle. *Gaz. des Hôp.*, 1867, pp. 519, 531, 555.
63. CLARKE, LOCKHART. Complete division of the median nerve with preservation of sensibility (RICHEL'S case). *Lancet*, 1867, vol. 2, p. 747.
64. KIALLMARK, H. *Lancet*, 1867, vol. 2, p. 747.
65. SAPPEY. Recherches sur les nerfs du névritème ou nervi nervorum. *Compt. Rend. de l'Acad.*, vol. 65, 1867, p. 761.
66. —Recherches sur la structure de l'enveloppe fibreuse des nerfs. *Journ. de l'Anat. et de la Physiol.*, 1868, p. 47.
67. LAVERAN, A. Recherches expérimentales sur la régénération des nerfs. Thèse de Strasbourg. *Journ. de l'Anat. et de la Physiol.*, 1868, p. 305.
68. NEUMANN. Degeneration und Regeneration nach Nervendurchschneidung. *Archiv der Heilkunde*, IX., 1868, p. 193.
69. ROBIN. Observations histologiques sur la génération et la régénération des nerfs. *Journ. de l'Anat. et de la Physiol.*, 1868, p. 321.
70. ARLOING ET TRIPIER. Recherches sur les effets des sections et des résections nerveuses relativement à l'état de la sensibilité dans les téguments et le bout périphérique des nerfs. *Compt. Rend. de l'Acad.*, vol. 67, 1868, p. 1058; vol. 68, 1869, p. 547.
71. SAVORY. A case in which, after removal of several inches of the musculo-spiral nerve, the sensibility of that part of the skin of the hand which is supplied by it was retained. *Lancet*, 1868, vol. 2, p. 142.
72. HERTZ, H. Ueber Degeneration und Regeneration durchschnittener Nerven. *VIRCHOW'S Archiv*, 1869, vol. 46, p. 257.
73. LÉTIÉVANT. Phénomènes physiologiques et pathologiques consécutifs à la section des nerfs principaux du bras. [Lyon Méd. No. 21-22, 1869.] VIRCHOW-HIRSCH, Jahresbericht, 1869, vol. 2, pp. 291 and 321.
74. BRUNS. Das Ranken-Neurom. *VIRCHOW'S Archiv*, 1870, vol. 50, p. 80.
75. JESSOP. Traumatic neuroma causing paralysis: rapid and complete restoration of the function of the nerve after removal of the tumour. *Brit. Med. Jour.*, 1871, vol. 2, p. 640.

76. BÄRWINKEL, FR. Ueber ein prognostisch wichtiges Symptom traumatischer Lähmungen. *Archiv der Heilkunde*, XII., 1871, p. 336.
77. VULPIAN. Recherches relatives à l'influence des lésions traumatiques des nerfs sur les propriétés physiologiques et la structure des muscles. *Archives de Physiologie norm. et pathol.*, vol. 4, 1871, p. 745.
78. BENECKE. Ueber die histologischen Vorgänge in durchschnittenen Nerven. *VIRCHOW'S Archiv*, vol. 55, 1872, p. 496.
79. RANVIER. De la dégénérescence des nerfs après leur section. *Compt. Rend. de l'Acad.*, 1872, p. 1831.
80. MITCHELL, WEIR. *Injuries of Nerves*. Lond., 1872.
81. RANVIER. De la régénération des nerfs sectionnés. *Compt. Rend. de l'Acad.*, 1873, p. 491.
82. LÉTIÉVANT. *Traité des sections nerveuses*. Paris, 1873.
83. EICHHORST. Ueber Nervendegeneration und Nervenregeneration. *VIRCHOW'S Archiv*, 1874, vol. 59, p. 1.
84. ERB, W. *Krankheiten des Nervensystems*. *Handbuch der speciellen Pathologie u. Therapie v. Ziemssen*. Leipzig, vol. 12; Hälfte 1, p. 373.
85. SCHMIDT. On the construction of the dark or double-bordered nerve fibres. *Monthly Microscop. Journ.*, 1874, vol. 11, p. 200.
86. VULPIAN. Note sur la régénération dite autogénique des nerfs. [*Archives de Physiol. norm. et pathol.*, 1874, Nos. 4 and 5.] *VIRCHOW-HIRSCH, Jahresbericht*, 1874, vol. 1, p. 70.
87. REMAK. Zur vicariirenden Function peripherer Nerven des Menschen. [*Berl. Klin. Wochenschr.*, 1874, Nos. 48-49.] *VIRCHOW-HIRSCH, Jahresbericht*, 1874, vol. 2, p. 131.
88. RINDFLEISCH, ED. *Lehrbuch der pathologischen Gewebelehre*. Leipzig, 1875, 4 Aufl., p. 20.
89. KEY u. RETZIUS. *Studien in der Anatomie des Nervensystems und des Bindegewebes*. Stockholm, 1876, Hälfte 2.
90. MITCHELL, WEIR, and BERTOLET, R.M. Neurotomy, with an examination of the Regenerated Nerves and notes upon Neural Repair. *The American Journ. of the Med. Sciences*, vol. 71, 1876, p. 321.
91. KRAUSSOLD, H. Beitrag zur Nerven Chirurgie; Sarcom des N. medianus; Resection eines 11 centim.-langen Stückes; keine Sensibilitätsstörungen. *Archiv f. klin. Chirurg. v. LANGENBECK*, 1877, vol. 21, p. 448.
92. LANTERMAN, A. J. Ueber den feineren Bau der markhaltigen Nervenfasern. *Archiv f. Mikros. Anat.*, vol. 13, 1877, p. 1.
93. BALFOUR. The Development of Elasmobranch Fishes. *Journ. of Anat. and Physiol.*, vol. 11, 1877, p. 406. *Development of the Spinal Nerves*, p. 422.
94. BAKOWIECKI. Zur Frage vom Verwachsen der peripherischen Nerven. *Archiv f. Mikros. Anat.*, vol. 13, 1877, p. 420.

95. KUHN, J. H. Die peripherische markhaltige Nervenfasern. *Archiv f. Mikros. Anat.*, vol. 13, 1877, p. 427.
96. BERT. Sur la transmission des excitations dans les nerfs de sensibilité. *Compt. Rend. de l'Acad.*, vol. 84, 1877, p. 173.
97. MARSHALL, MILNES. On the Early Stages of Development of the Nerves in Birds. *Journ. of Anat. and Physiol.*, vol. 11, 1877, p. 491.
98. GLUCK, TH. Experimentelles zur Frage der Nerven-naht und der Nerven-regeneration. *VIRCHOW'S Archiv*, vol. 72, 1878, p. 624.
99. WHEELHOUSE. Address in Surgery. *Brit. Med. Journ.*, 1878, vol. 2, p. 204.
100. MEYER, S. Ueber Degenerations- und Regenerations-vorgänge im normalen peripherischen Nerven. *Wiener Akad. Sitzungsber., Math.-natur. Classe*, vol. 77, Part III., p. 80.
101. KRAUSSOLD, H. Ueber Nervendurchschneidung und Nerven-naht. *VOLKMANN'S Sammlung Klin. Vorträge*, 1878, No. 132.
102. RANVIER. *Leçons sur l'histologie du système nerveux*. Paris, 1878.
103. KORYBUTT-DASZKIEWICZ. Degeneration und Regeneration markhaltiger Nervenfasern nach Traumen. [Inaug.-Dissert. Strassburg, 1878.] *VIRCHOW-HIRSCH, Jahresbericht*, 1878, vol. 1, p. 47.
104. AUFRECHT. Die Ergebnisse eines Falles von subacuter Spinal-Paralyse, insbesondere für die Lehre von der Muskeln- und Nerven-Regeneration. *Deutsch. Archiv f. Klin. Med.*, 1878, vol. 22, p. 33.
105. KORYBUTT-DASZKIEWICZ. Ueber die Entwicklung der Nerven aus Plasmazellen beim Frosche. *Archiv f. Mikros. Anat.*, 1878, vol. 15, p. 1.
106. COLASANTI, G. Ueber die Degeneration durchschnittener Nerven. *Archiv f. Anat. u. Physiol. (Physiol. Abth.)*, 1878, p. 206.
107. TIZZONI, G. Zur Pathologie des Nervengewebes. *Centralblatt f. die Med. Wissensch.*, 1878, No. 13, p. 225.
108. MEYER, S. Ueber Degenerations- und Regenerations-vorgänge im unversehrten peripherischen Nerven. [Prager Med. Wochenschr., No. 51, 1879.] *VIRCHOW-HIRSCH, Jahresbericht*, 1879, vol. 1, p. 40.
109. KÖLLIKER, ALBERT. *Entwicklungsgeschichte des Menschen und der höheren Thiere*. Leipzig, 1879, 2nd edit., p. 600.
110. HULKE. On a case of sutural junction of the ulnar nerve, fifteen weeks after its complete severance by a roofing-slate; early restoration of function. *The Med. Press and Circular*, 1879, p. 333.
111. HIS. Ueber die Anfänge des peripherischen Nervensystems. *Archiv f. Anat. u. Physiol. (Anat. Abth.)*, 1879, p. 455.
112. NEUMANN, E. Ueber Degeneration und Regeneration zerquetschter Nerven. *Archiv f. Mikros. Anat.*, 1880, vol. 18, p. 302.
113. GLUCK, TH. Ueber Neuroplastik auf dem Wege der Transplantation. *Archiv f. Klin. Chirurg. v. LANGENBECK*, 1880, vol. 25, p. 606.

114. REMAK. Berl. Klin. Wochenschr., 1880, 1. März., p. 126.
115. HOGGAN. On Degeneration and Regeneration of the Axis-cylinder in non-traumatic Nerve Lesions, with special reference to gangrene of the cutaneous nerves. Trans. Path. Soc. Lond., 1880, vol. 31, p. 12.
116. LEEGAARD. Ueber die Entartungsreaction. Deutsch. Archiv f. Klin. Med., 1880, vol. 26, p. 459.
117. WOLBERG, L. Kritisch-experimentelle Untersuchungen über die Nervennaht und Nervenregeneration. Vorläufige Mittheilung. Centralblatt f. Chirurgie, No. 38, 1881, p. 593.
118. FALKENHEIM, H. Zur Lehre von der Nervennaht und der prima intentio nervorum. Inaug. Dissert., Königsberg, 1881; Deutsch. Zeitsch. f. Chirurg., vol. 16, 1882, p. 31.
119. CORNIL et RANVIER. Manuel d'histologie pathologique. Paris, 1881, 2de edit., vol 1, p. 661.
120. OGSTON. Suture of the Ulnar Nerve. Brit. Med. Journ., 1881, vol. 1, p. 391.
121. BALFOUR, F. M. A Treatise on Comparative Embryology. London, 1881. vol. 2, p. 369.
122. VANLAIR, C. De la régénération des nerfs périphériques par le procédé de la suture tubulaire. Archives de Biologie, 1882, vol. 3, p. 379.
123. TILLMANN, H. Ueber Nervenverletzungen und Nervennaht. Archiv f. Klin. Chirurg. v. LANGENBECK, 1882, vol. 27, p. 1.
124. BUSCH. Ueber Nervennaht. Archiv f. Klin. Chirurg. v. LANGENBECK, 1882, vol. 27, p. 327.
125. MEYER, S. Ueber Vorgänge der De- und Regeneration im unversehrten peripherischen Nervensystem. [Prager Zeitschr. f. Heilk., parts 2 and 3.] VIRCHOW-HIRSCH, Jahresbericht, 1882, vol. 1, p. 267.
126. NICAISE. International Encyclop. of Surgery. London, 1883, vol. 3, p. 545.
127. WOLBERG, L. Kritische und experimentelle Untersuchungen über die Nervennaht und Nervenregeneration. Deutsche Zeitschr. f. Chirurg., vol. 18, 1883, pp. 293, 484; vol. 19, p. 82.
128. PEYRANI, C. Ueber die Degeneration durchschnittener Nervenfasern. [Biolog. Centralblatt, vol. 3, 1883, p. 23.] VIRCHOW-HIRSCH, Jahresber., 1883, vol. 1, p. 285.
129. HOLMES. On a Case of Suture of the Musculo-spiral Nerve five months after its complete Division. Lancet, 1883, vol. 1, p. 1034.
130. PAGE. Case of Secondary Suture of Ulnar Nerve six months after its Division. Brit. Med. Journ., 1883, vol. 1, p. 1223.
131. VIGNAL, M. Mémoire sur le développement des tubes nerveux chez les embryons des mammifères. [Archives de Physiol. norm. et path., 2 ser., No. 4, p. 514.] VIRCHOW-HIRSCH, Jahresber., 1883, vol. 1, p. 107.
132. KASPER. Zur Casuistik der Neurome. Inaug. Dissert., Greifswald, 1883.

133. FRIEDLÄNDER und KRAUSE. Ueber Veränderungen der Nerven und des Rückenmarks nach Amputationen. Fortschritte d. Med., vol. 4, 1886, No. 23, p. 749.
134. KÖLLIKER. Histologische Studien an Batrachierlarven. Zeitsch. f. Wissensch. Zool., vol. 43, 1886, p. 1.
135. BOWLBY, ANTHONY A. Dictionary of Practical Surgery, HEATH'S. London, 1887, vol. 2, p. 61.
136. KRAUSE, F. Ueber aufsteigende und absteigende Nervendegeneration. Verhandlung der physiol. Gesellsch. zu Berl., Jan. 14, 1887; Archiv f. Anat. u. Physiol. (Physiol. Abth.), 1887, p. 370.
137. MACCORMAC. Cases of Secondary Nerve Suture. WAGSTAFFE. Lond. Med. Record, 1887, p. 279.
138. VANLAIR, C. Nouvelles recherches expérimentales sur la régénération des nerfs. Archives de Biol., 1887, vol. 6, p. 127.
139. CATTANI, G. Sulla degenerazione e neoformazione delle fibre nervose periferiche. [Archivio per le Sc. Med., vol. 11, No. 11.] VIRCHOW-HIRSCH, Jahresber., 1887, vol. 1, p. 266.
140. TANGL, F. Zur Histologie der gequetschten peripherischen Nerven. Archiv f. Mikros. Anat., vol. 29, 1887, p. 464.
141. JACOBI, RUD. Ein merkwürdiges Sensibilitätsphänomen. Berl. Kl. Wochenschr., Juni, 1887, pp. 412, 452.
142. HOCHWART. Ueber De- und Regeneration von Nervenfasern. [Wien. Med. Jahrb. N. F., II., 1, p. 1, 1887.] SCHMIDT'S Jahrbücher, 1887, vol. 215, p. 17; vol. 216, p. 130.
143. HANKEN. Ueber die Folgen von Quetschung peripherischer Nerven. [Internat. Mon. Schr. f. Anat. u. Histol., III., 8, p. 265.] SCHMIDT'S Jahrbücher, vol. 216, p. 129.
144. HIS. Die Entwicklung der ersten Nervenbahnen beim menschlichen Embryo. Uebersichtliche Darstellung. Archiv f. Anat. u. Physiol. (Anat. Abth.), 1887, p. 368.
145. GOTTSACKER, ANTON. Ueber Stumpfneurome. Inaug. Dissert., Bonn, 1889.
146. BOWLBY, ANTHONY. Injuries and Diseases of Nerves and their Surgical Treatment. London, 1889.
147. HIS. Die Neuroblasten und deren Entstehung im embryonalen Mark. Archiv f. Anat. u. Physiol. (Anat. Abth.), 1889, p. 249.
148. ROSE, EDMUND. Eine Knöchelamputation mit spontaner Nervenregeneration. Aus der freien Vereinigung der Chirurgen Berlins, 1890. Beiträge zur Conservativen Chirurgie, p. 461.
149. TEUSCHER. Ueber Degeneration am normalen peripheren Nerven. Archiv f. Mikr. Anat., 1890, vol. 36, p. 579.

150. v. BÜNGNER, OTTO. Ueber die Degenerations- und Regenerationsvorgänge am Nerven nach Verletzungen. ZIEGLER'S Beiträge zur Patholog. Anat., vol. 10, 1891, p. 321.
151. MITROPHANOW. Sur la formation du système nerveux périphérique des Vertébrés. Compt. Rend. de l'Acad., vol. 113, 1891, p. 659.
152. HARRISSON. Nerve Grafting. Lancet, 1892, vol. 1, p. 691.
153. VANLAIR, C. Des altérations nerveuses centripètes consécutives à la section des nerfs et aux amputations des membres. [Bruxelles, Acad. Royale de Méd. de Belgique.] VIRCHOW-HIRSCH, Jahresber., 1892, II., p. 282.
154. HUBER, G. CARL. Ueber das Verhalten der Kerne der Schwann'schen Scheide bei Nervendegeneration. Archiv f. Mikros. Anat., vol. 40, 1892, p. 409.
155. v. BÜNGNER. Bemerkung zu der Arbeit von Professor G. C. HUBER. Archiv f. Mikros. Anat., vol. 41, 1893, p. 146.
156. HOWELL and HUBER. A Physiological, Histological, and Clinical Study of the Degeneration and Regeneration in Peripheral Nerve Fibres after Severance of their Connections with the Nerve Centres. Journ. of Physiol., vol. 13, 1892, p. 335; vol. 14, 1893, p. 1.
157. VANLAIR, C. Survie après la section des deux nerfs vagues. Compt. Rend. de l'Acad., vol. 116, 1893, p. 330.
158. STROEBE. Experimentelle Untersuchungen über Degeneration und Regeneration peripherer Nerven nach Verletzungen. ZIEGLER'S Beiträge, 1893, vol. 13, p. 160.
159. v. NOTTHAFT. Neue Untersuchungen über den Verlauf der Degenerations- und Regenerationsprocesse am verletzten peripheren Nerven. Zeitschr. f. Wissensch. Zool., vol. 55, 1893, p. 134.
160. VANLAIR, C. Recherches chronométriques sur la régénération des nerfs. Archives de Physiol. norm. et patholog., 5th Series, vol. 6, 1894, p. 217.
161. HAMMER. Ueber Degeneration im normalen peripheren Nerven. Archiv f. Mikros. Anat., vol. 45, 1895, p. 145.
162. HUBER, G. CARL. A Study of the Operative Treatment for Loss of Nerve Substance in Peripheral Nerves. Journ. of Morphol., vol. 11, 1895, p. 629.
163. BERGMAN, E. Ueber die aufsteigende Degeneration der sensiblen und motorischen Gehirnnerven. [Pamiętnick Towarzystwa Lekarskiego Warszawskiego, 1895, vol. 91, p. 25.] VIRCHOW'S Jahresber., 1895, vol. 1, p. 221.
164. FLEMING, ROBERT A. Some Notes on Ascending Degeneration (so-called), and on the Changes in Nerve Cells consequent thereon. Brit. Med. Journ., 1896, vol. 2, p. 918.
165. ROBSON, MAYO. A Case in which the Spinal Cord of a Rabbit was successfully used as a Graft in the Median Nerve of a Man. Brit. Med. Journ., 1896, vol. 2, p. 1312.

EXPLANATION OF PLATES 4-9.

PLATE 4.

- Fig. 1. Hands of Case I., before operation. Suture of median and ulnar nerves six-and-a-half months after division. Sound hand for comparison. Shows difference in quality of skin, loss of flexures, atrophy, sore on inner side of first internode of little finger, transverse depressed lines on nails, and the characteristic attitude. $\frac{1}{2}$ nat. size.
- Fig. 2. Hand of Case I., before operation. Lateral view. Shows position in which the hand was carried at the wrist, lines on nail of thumb, atrophy of thenar eminence, and part of the cutaneous cicatrix from wound in forearm. $\frac{1}{2}$ nat. size.

PLATE 5.

- Fig. 1. Hand of Case II., with left hand for comparison, one year after operation of suture of the median three months after division. Shows restored thenar eminence and extent to which hand can be opened. $\frac{2}{7}$ nat. size.
- Fig. 2. Same. Shows extent to which hand can be closed. The inability to bring the tips of the index and middle fingers by complete flexion of their terminal phalanges into the centre of the palm is displayed. Operation cicatrix shown in middle line above wrist. $\frac{2}{7}$ nat. size.
- Fig. 3. Hand of Case IV., before operation. Section of ulnar nerve of eighteen months' standing. Shows over-extension of the first phalanges and flexion of the second and third phalanges of the little and ring fingers, and the atrophy of the hypothenar eminence. The transverse cicatrix of wound above wrist is shown. $\frac{1}{2}$ nat. size.

PLATE 6.

- Fig. 1. Hand of Case III., with right hand for comparison, before operation. Two months after fracture at elbow joint. Shows position in which fingers and thumb were carried, and the atrophy of the thenar and hypothenar eminences. $\frac{1}{2}$ nat. size.
- Fig. 2. Same. Shows hollowing out of palm and flexion at wrist. $\frac{2}{3}$ nat. size.

PLATE 7.

- Fig. 1. Longitudinal section central bulb, ulnar nerve. Case I. Near centre three small bundles grouped together, and separated by layers of connective

tissue, and each containing an enormous number of young nerve fibres, in which are displayed the axis-cylinders, each surrounded by a clear zone. A bundle also shown longitudinally, the fibres showing in parts the delicate axis-cylinder with granular deposit of myeline around, and also oval nuclei. ZEISS, Obj. D. $\frac{340}{1}$. Cf. figs. 2 and 3.

- Fig. 2. Longitudinal section bulb from peripheral end of ulnar. Case I. Shows young nerve fibres identical in appearance with those in central bulb (fig. 1). Many nerve fibres in each bundle. Distinct axis-cylinders. The nuclei in the bundles are distinct from the nerve fibres. ZEISS, Obj. D. $\frac{340}{1}$. Cf. fig. 4.
- Fig. 3. Same as in fig. 1. (Central end.) Part of largest bundle taking an oblique course. ZEISS, Obj. F. $\frac{600}{1}$.
- Fig. 4. Same as in fig. 2. (Peripheral end.) Shows young nerve fibres with axis-cylinders and clear surrounding zone, and many nuclei interspersed among fibres. ZEISS, Obj. F. $\frac{600}{1}$.
- Fig. 5. Longitudinal section ulnar nerve at entrance to central bulb. Case I. Transition from old to young nerve fibres. Shows old fibre diminishing and giving place to young nerve fibres with spindle-shaped nuclei. At one side a bundle of young nerve fibres less than double the diameter of an old fibre, showing young nerve fibres with axis-cylinders, granular myeline deposit, and spindle-shaped nuclei, attached to sides of young fibres. ZEISS, Obj. F. $\frac{600}{1}$.

PLATE 8.

- Fig. 1. Transverse section of ulnar nerve eighteen months divided, immediately proximal to the bulb on central end. Case IV. Portion of fasciculus. Shows normal perineurium and small bundles of young nerve fibres arranged like single old fibres. In some a delicate sheath surrounding the bundle. ZEISS, Obj. D. $\frac{340}{1}$.
- Fig. 2. Transverse section, base of cone from peripheral end of ulnar, eighteen months divided. Case IV. Shows compact tissue with small bundles of young nerve fibres cut transversely. Nuclei in the bundles besides nerve fibres. ZEISS, Obj. D. $\frac{340}{1}$.
- Fig. 3. Transverse section, proximal end of intercalary segment uniting ends of median. Case I. Dense groundwork of fibrous tissue containing in its meshes bundles of young nerve fibres showing nuclei. ZEISS, Obj. D. $\frac{340}{1}$.
- Fig. 4. Transverse section, distal end of same intercalary segment. Dense masses of fibrous tissue with a few bundles of transversely-cut young nerve fibres, and one bundle of young nerve fibres longitudinally cut. ZEISS, Obj. D. $\frac{340}{1}$.

- Fig. 5. Longitudinal (radial) section same intercalary segment. A portion at centre of mass. Shows several bundles of young nerve fibres transversely cut. ZEISS, Obj. F. $\frac{600}{1}$.
- Fig. 6. Another portion same section. Also at centre of mass. A bundle of young nerve fibres seen longitudinally. Shows axis-cylinders and commencing myeline deposit. ZEISS, Obj. F. $\frac{600}{1}$.

PLATE 9.

- Fig. 1. Transverse section, intercalary segment—distal end. Another part of same section shown in Plate 8, fig. 4. Shows numerous very small bundles of young nerve fibres. ZEISS, Obj. D. $\frac{340}{1}$.
- Fig. 2. Transverse section, proximal end of portion excised from median nerve. Case III. Nerve compressed at seat of fracture. Shows old myeline nerve fibres. Same appearance as section of normal nerve treated by same methods. ZEISS, Obj. D. $\frac{340}{1}$.
- Fig. 3. Transverse section, distal end of same portion of nerve. Shows normal perineurium, and small bundles of young nerve fibres, grouped as the single old fibres in fig. 2. Many of the bundles contain also nuclei and are surrounded by a delicate sheath. ZEISS, Obj. D. $\frac{340}{1}$.
- Fig. 4. Longitudinal section through point of transition from old to young nerve fibres in portion removed from musculo-spiral nerve. Case III. Two old fibres are seen terminating and giving place each to a bundle of young nerve fibres. ZEISS, Obj. F. $\frac{600}{1}$.
- Fig. 5. Transverse section same. Near centre, two very large old fibres, one of which shows at one side a slight thickening representing the nucleus and protoplasm of the sheath of SCHWANN, while the other shows at one side a large circular nucleus with two young nerve fibres at its side, all three structures lying between the myeline sheath and sheath of SCHWANN. ZEISS, Obj. F. $\frac{600}{1}$.
- Fig. 6. Same section. Portion of perineurium, and near centre, a bundle of young nerve fibres with two nuclei and the old myeline sheath and axis-cylinder at one side. ZEISS, Obj. F. $\frac{600}{1}$.
- Fig. 7. Same section. Near centre a bundle of young nerve fibres, with remains of old fibre at one side. ZEISS, Obj. F. $\frac{600}{1}$.

Fig. 1.

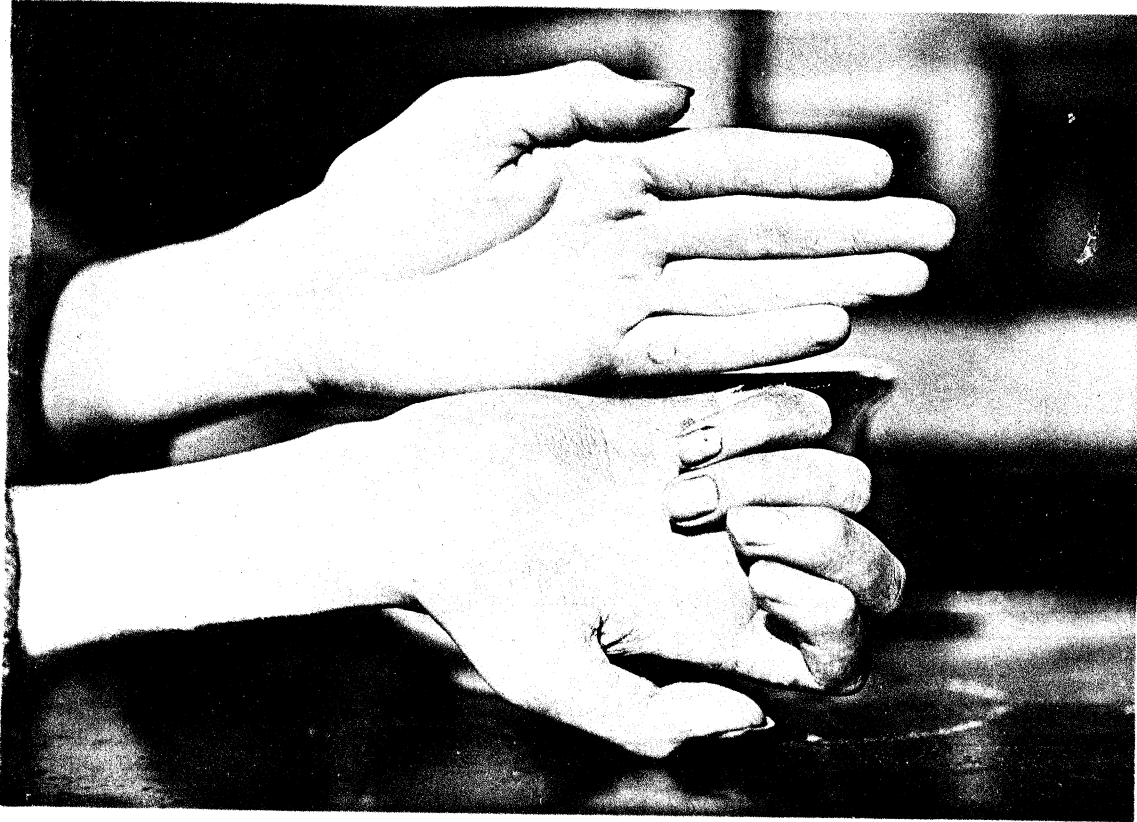

Fig. 2.

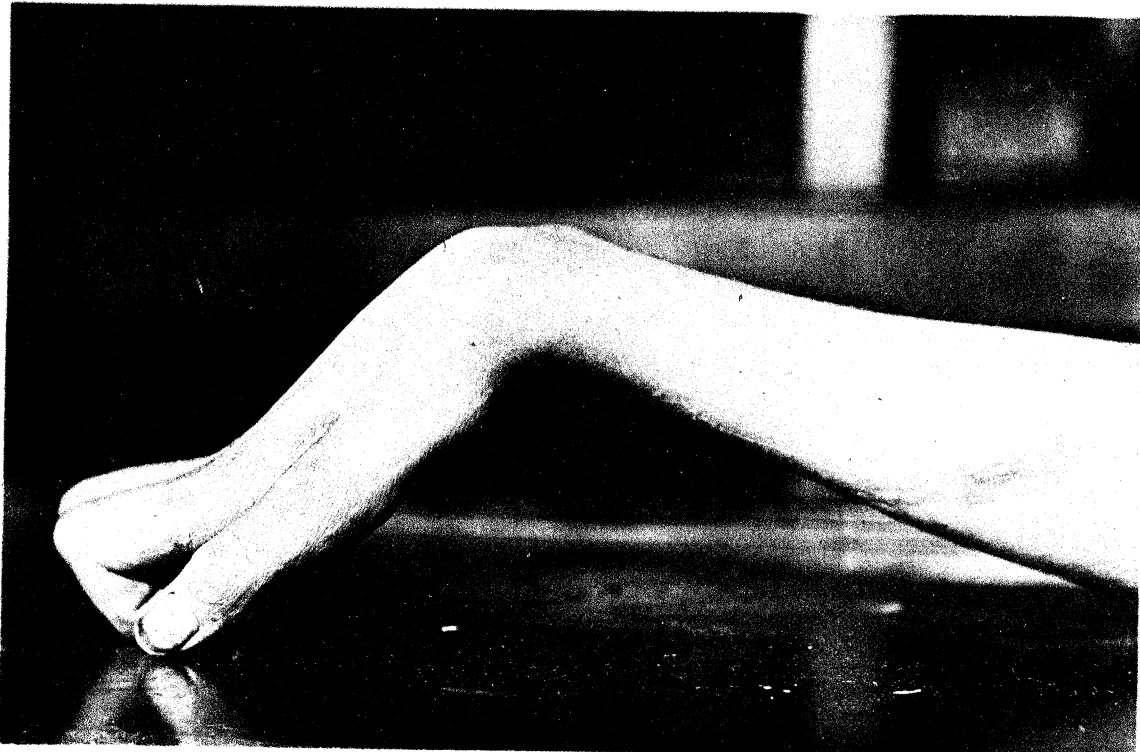

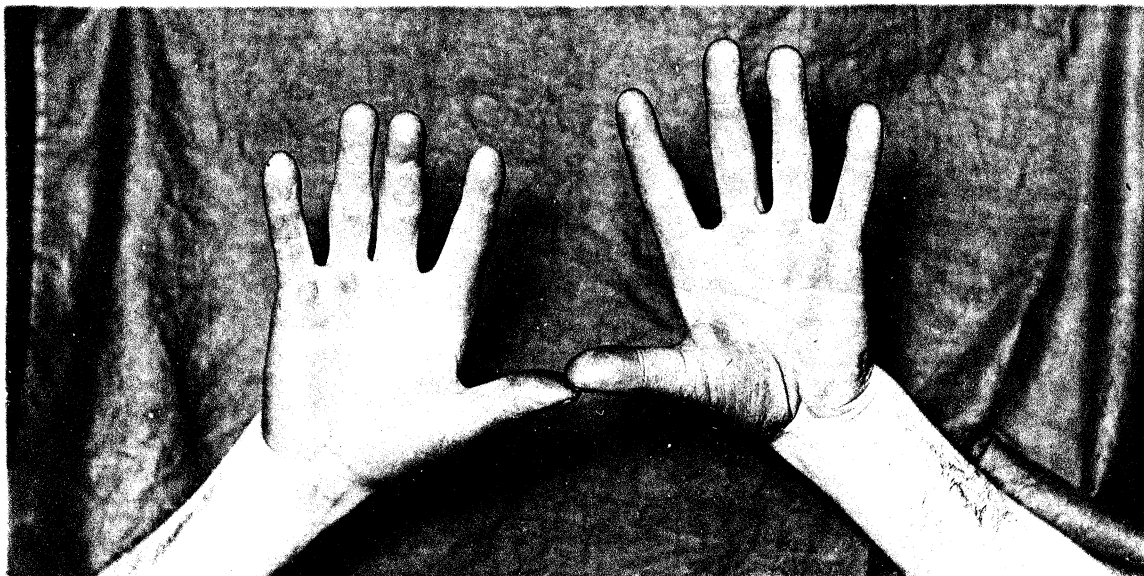


Fig. 2.

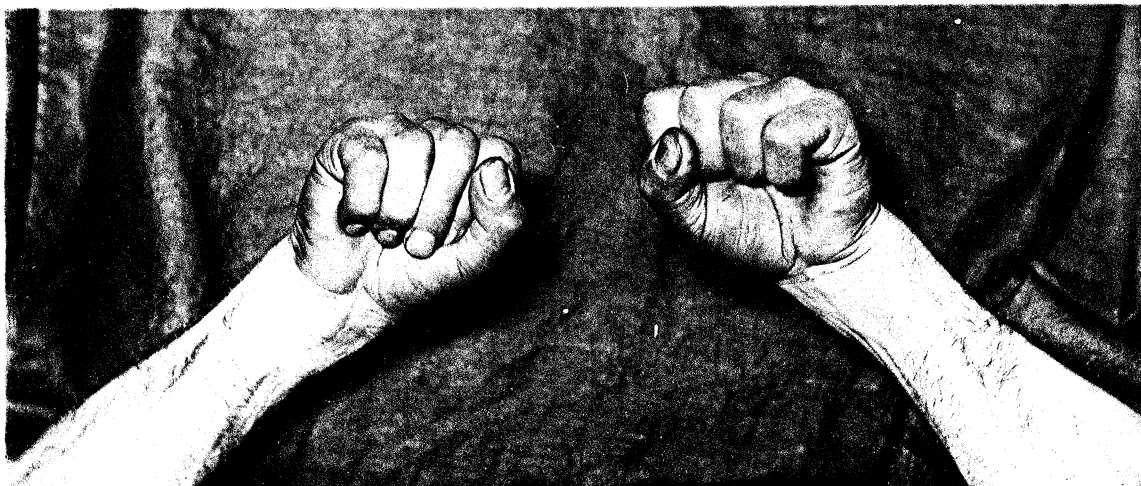
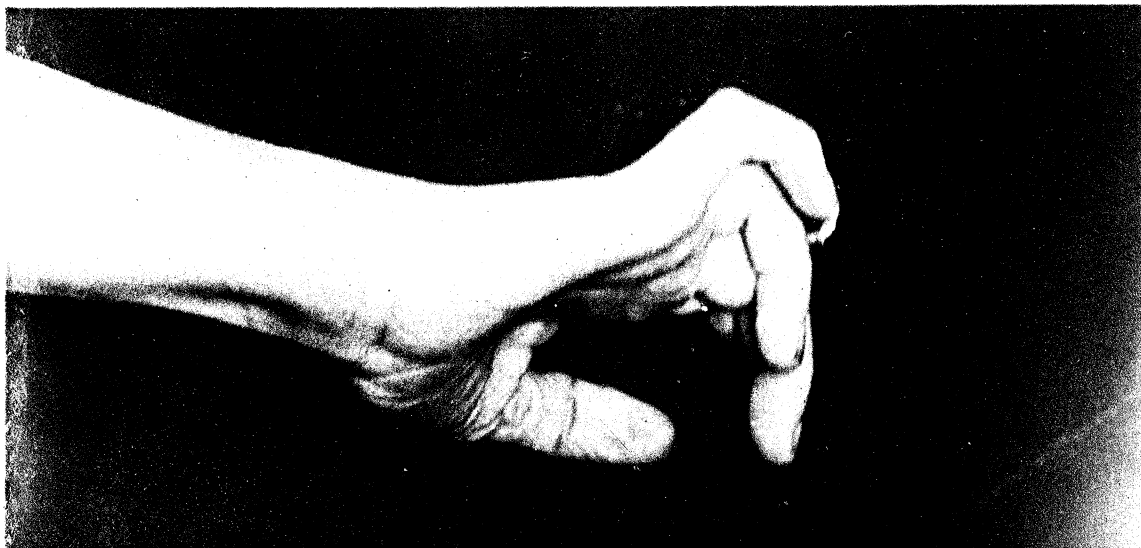

Fig. 3.



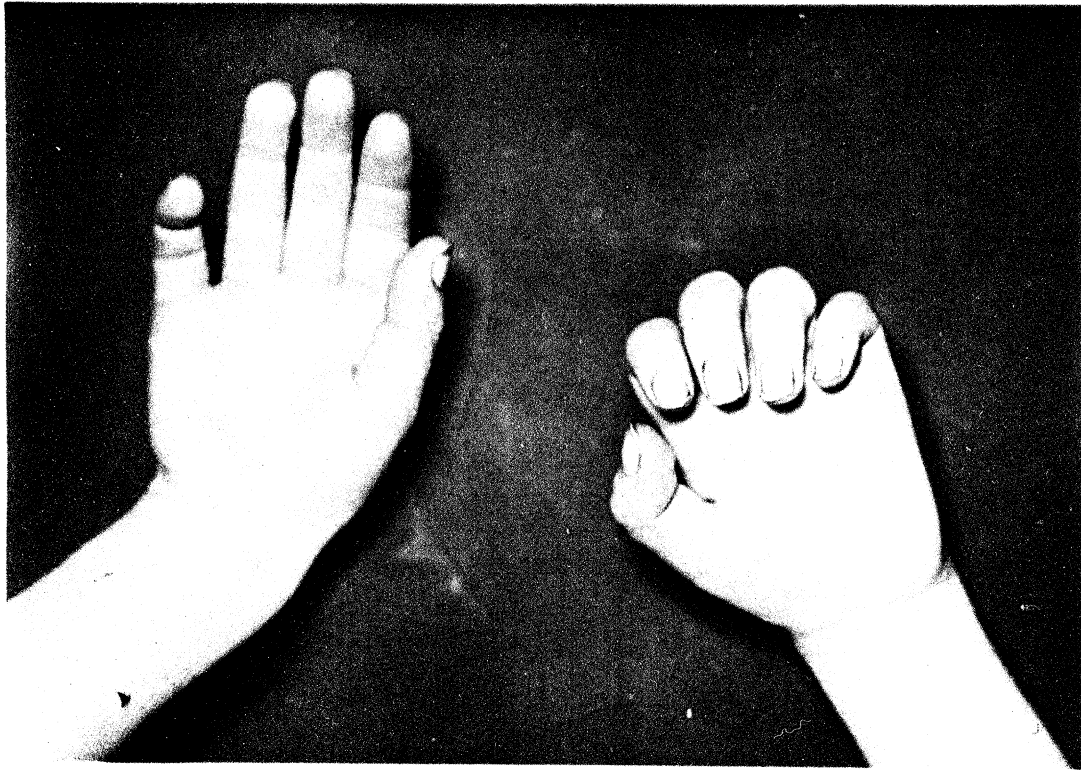
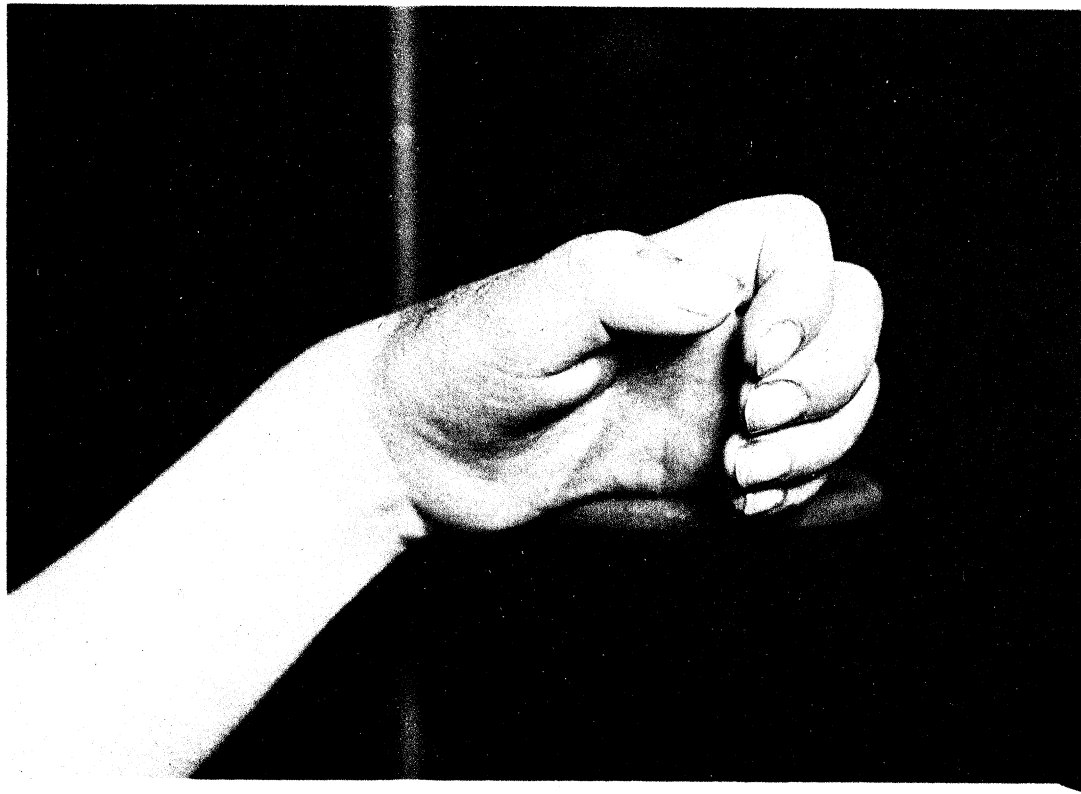


Fig. 2.



R. Kennedy. Photo.

Fig. 1.

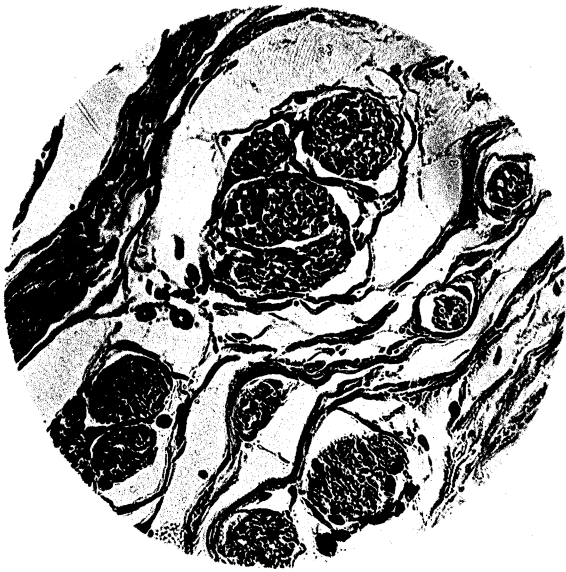

Fig. 2.

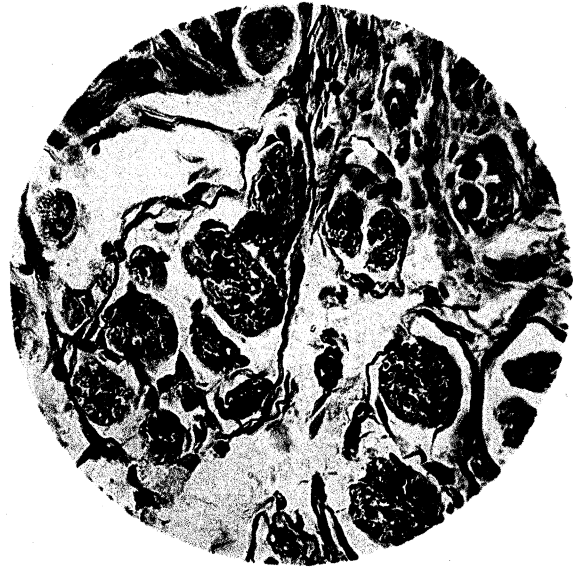

Fig. 3.

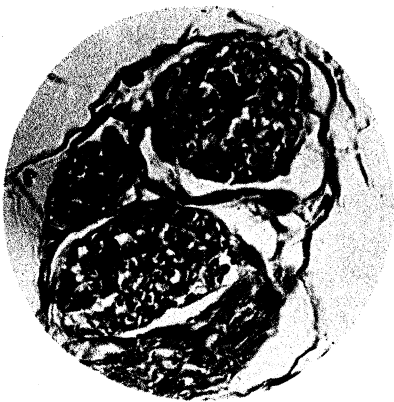


Fig. 4.

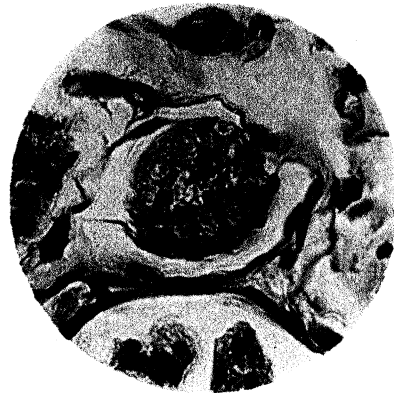


Fig. 5.

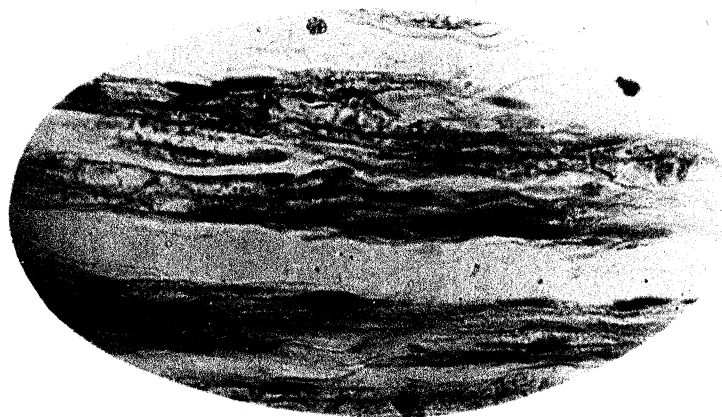


Fig. 1.

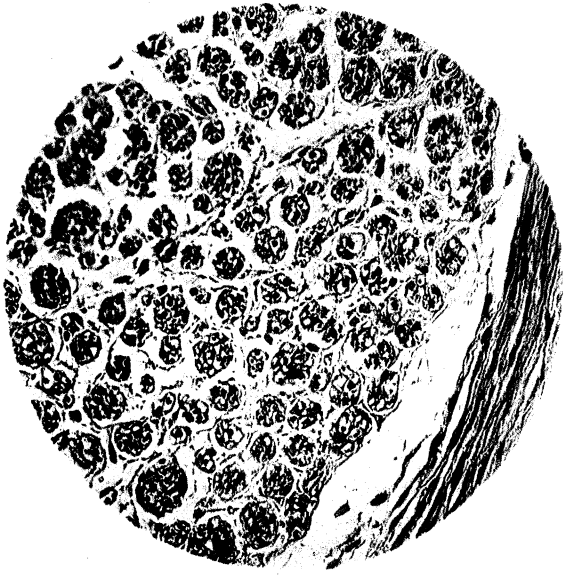


Fig. 2.

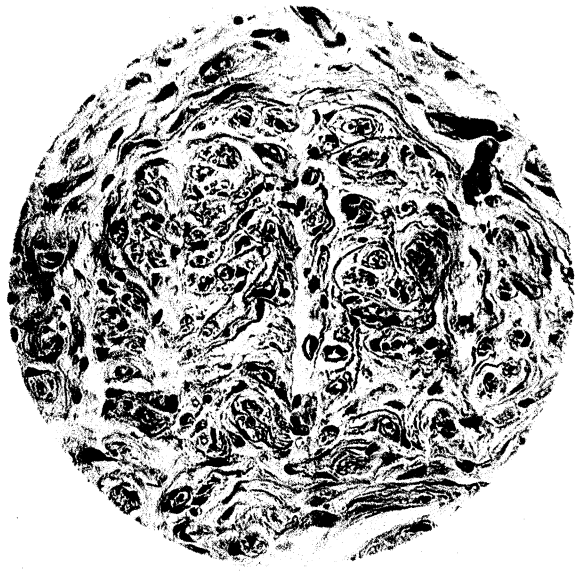


Fig. 3.

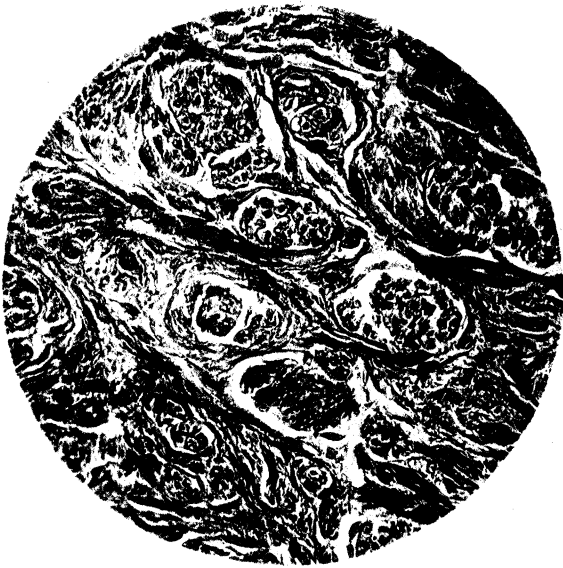

Fig. 4.

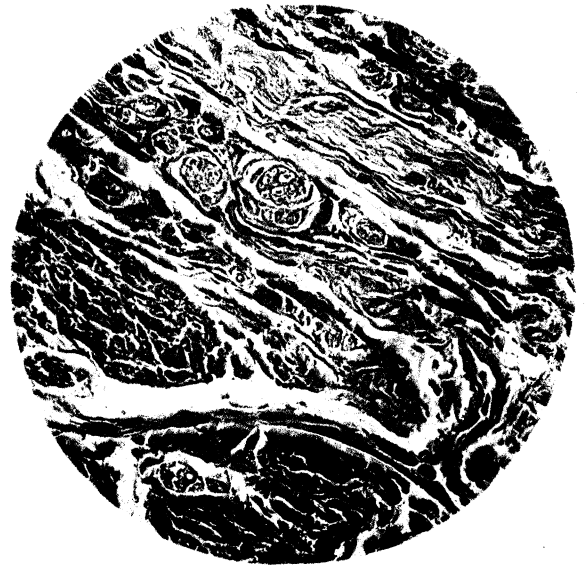

Fig. 5.

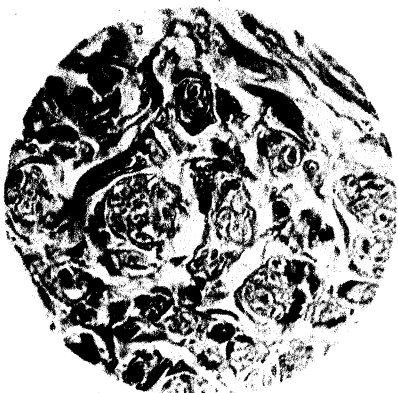


Fig. 6.



Fig. 1.




Fig. 2.

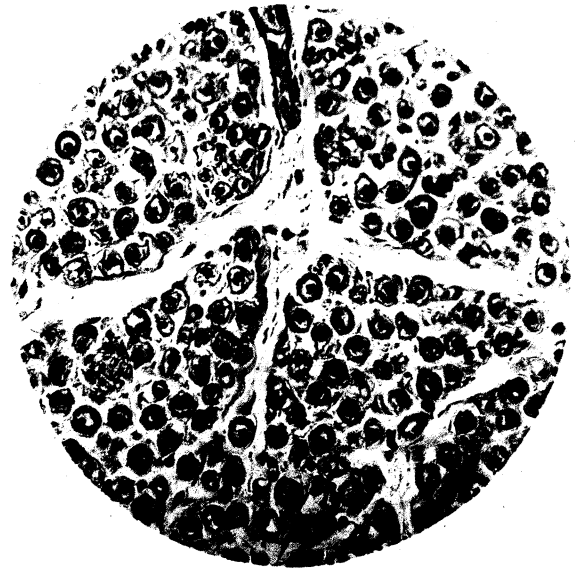


Fig. 3.

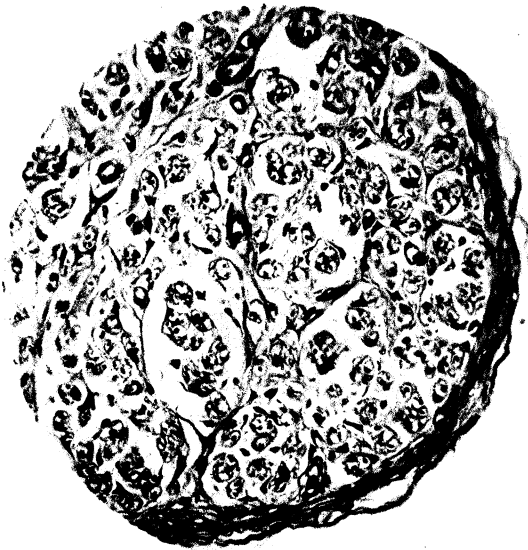


Fig. 4.



Fig. 5.

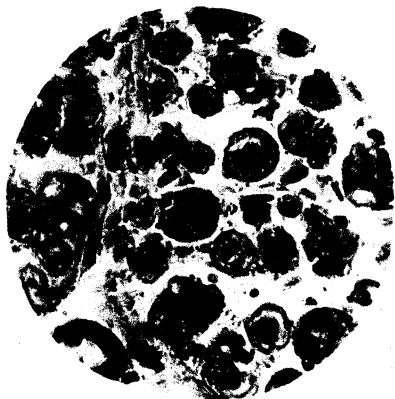


Fig. 6.




Fig. 7.



Fig. 1.



Fig. 2.



PLATE 4.

Fig. 1. Hands of Case I., before operation. Suture of median and ulnar nerves six-and-a-half months after division. Sound hand for comparison. Shows difference in quality of skin, loss of flexures, atrophy, sore on inner side of first internode of little finger, transverse depressed lines on nails, and the characteristic attitude. $\frac{1}{2}$ nat. size.

Fig. 2. Hand of Case I., before operation. Lateral view. Shows position in which the hand was carried at the wrist, lines on nail of thumb, atrophy of thenar eminence, and part of the cutaneous cicatrix from wound in forearm. $\frac{1}{2}$ nat. size.

Fig. 1.

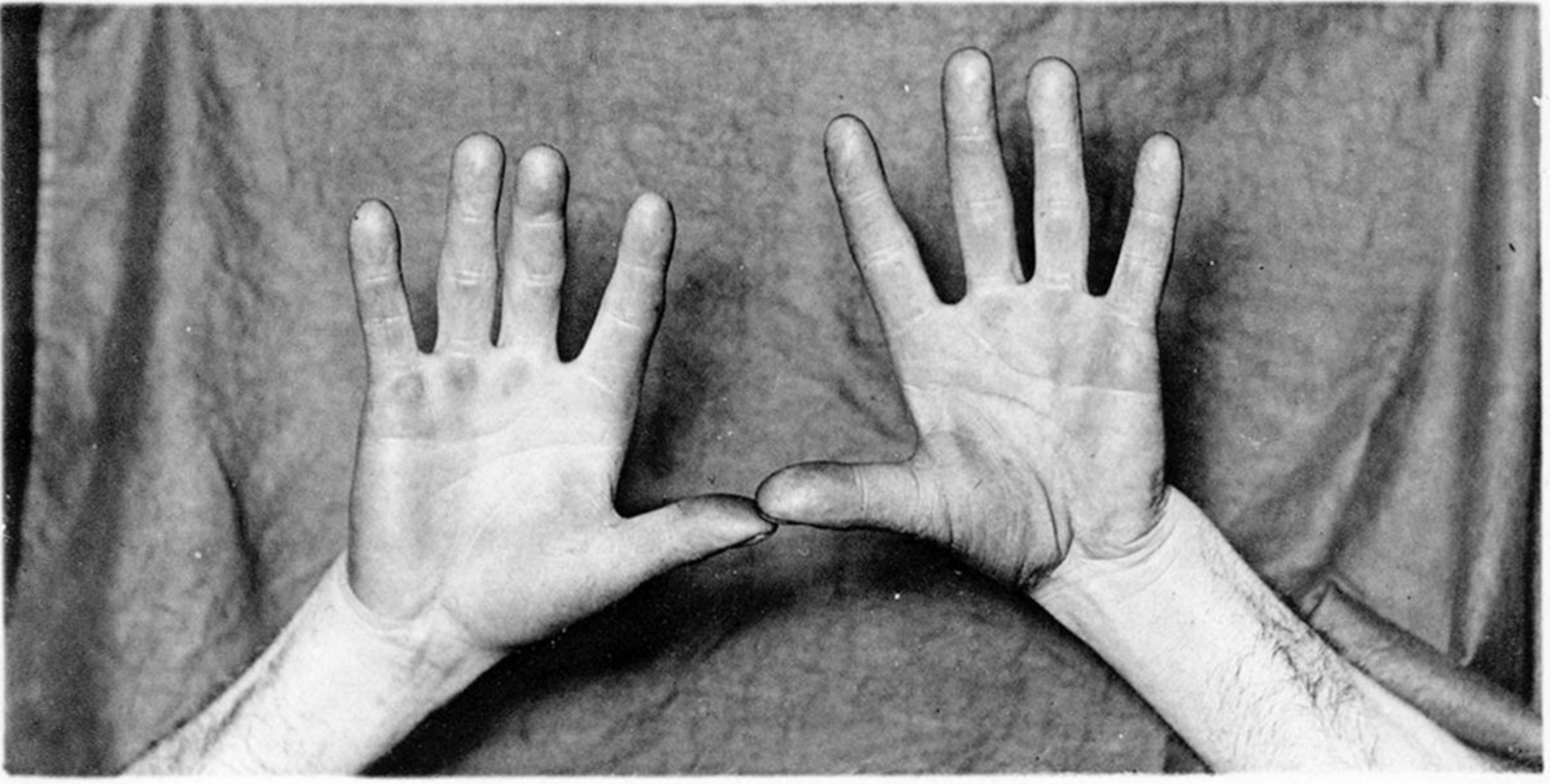


Fig. 2.

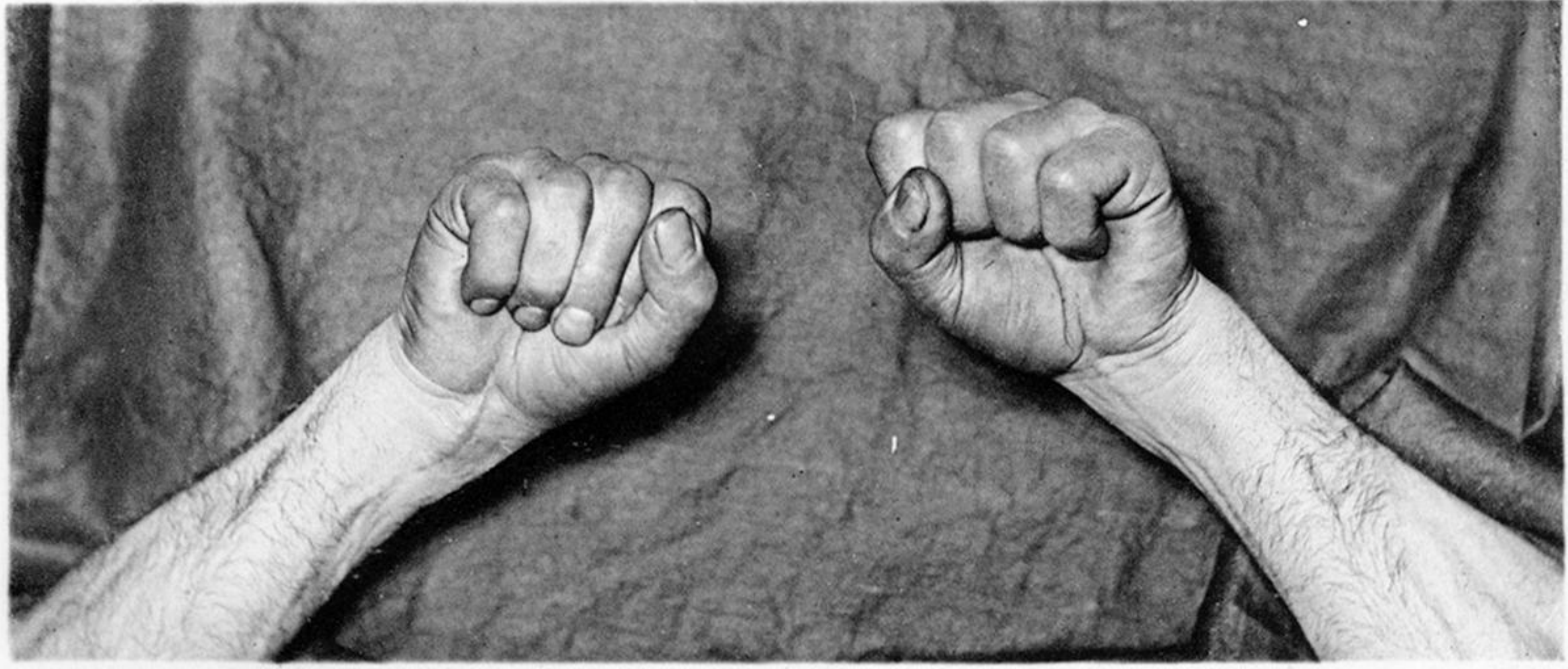


Fig. 3.

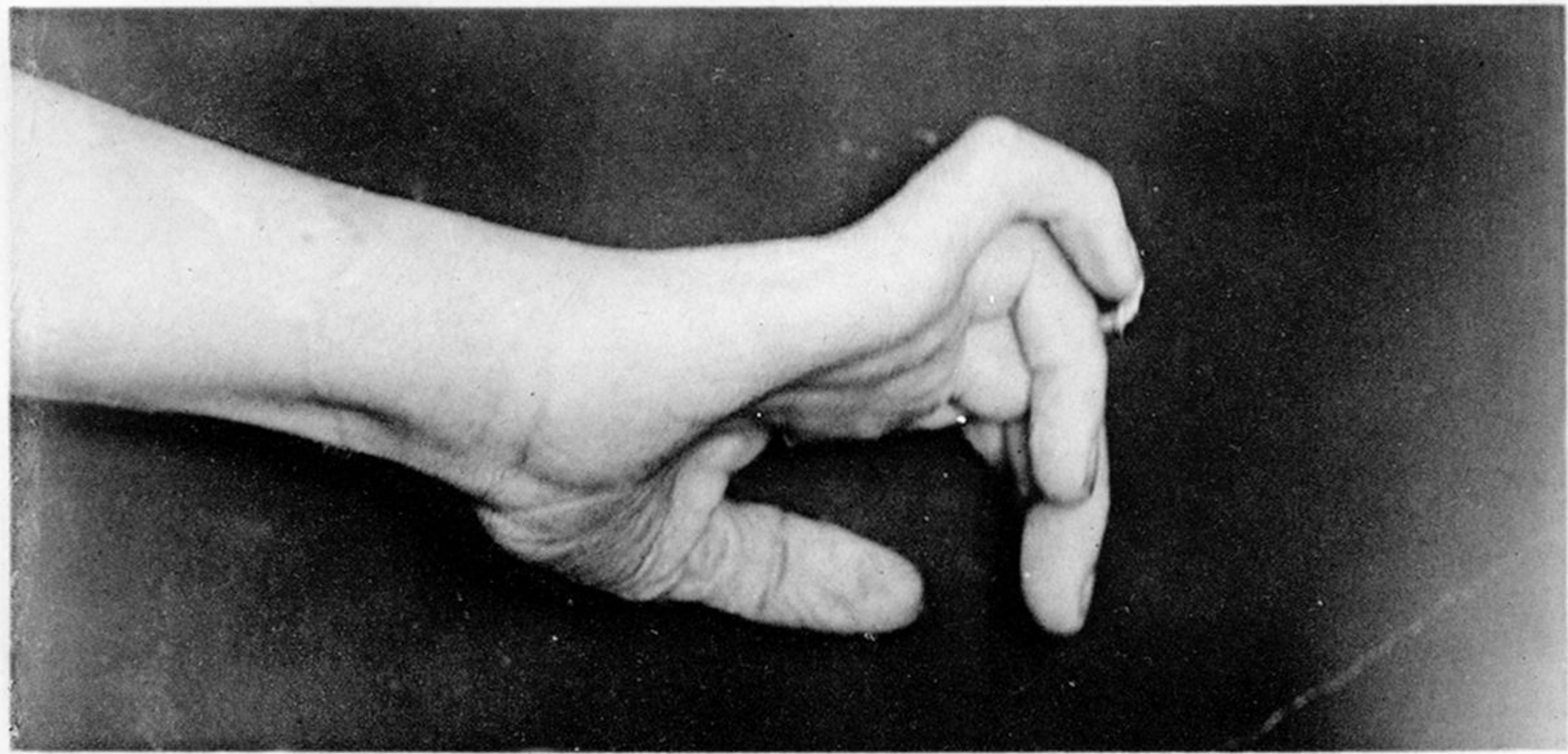


PLATE 5.

Fig. 1. Hand of Case II., with left hand for comparison, one year after operation of suture of the median three months after division. Shows restored thenar eminence and extent to which hand can be opened. $\frac{2}{7}$ nat. size.

Fig. 2. Same. Shows extent to which hand can be closed. The inability to bring the tips of the index and middle fingers by complete flexion of their terminal phalanges into the centre of the palm is displayed. Operation cicatrix shown in middle line above wrist. $\frac{2}{7}$ nat. size.

Fig. 3. Hand of Case IV., before operation. Section of ulnar nerve of eighteen months' standing. Shows over-extension of the first phalanges and flexion of the second and third phalanges of the little and ring fingers, and the atrophy of the hypothenar eminence. The transverse cicatrix of wound above wrist is shown. $\frac{1}{2}$ nat. size.

Fig. 1.

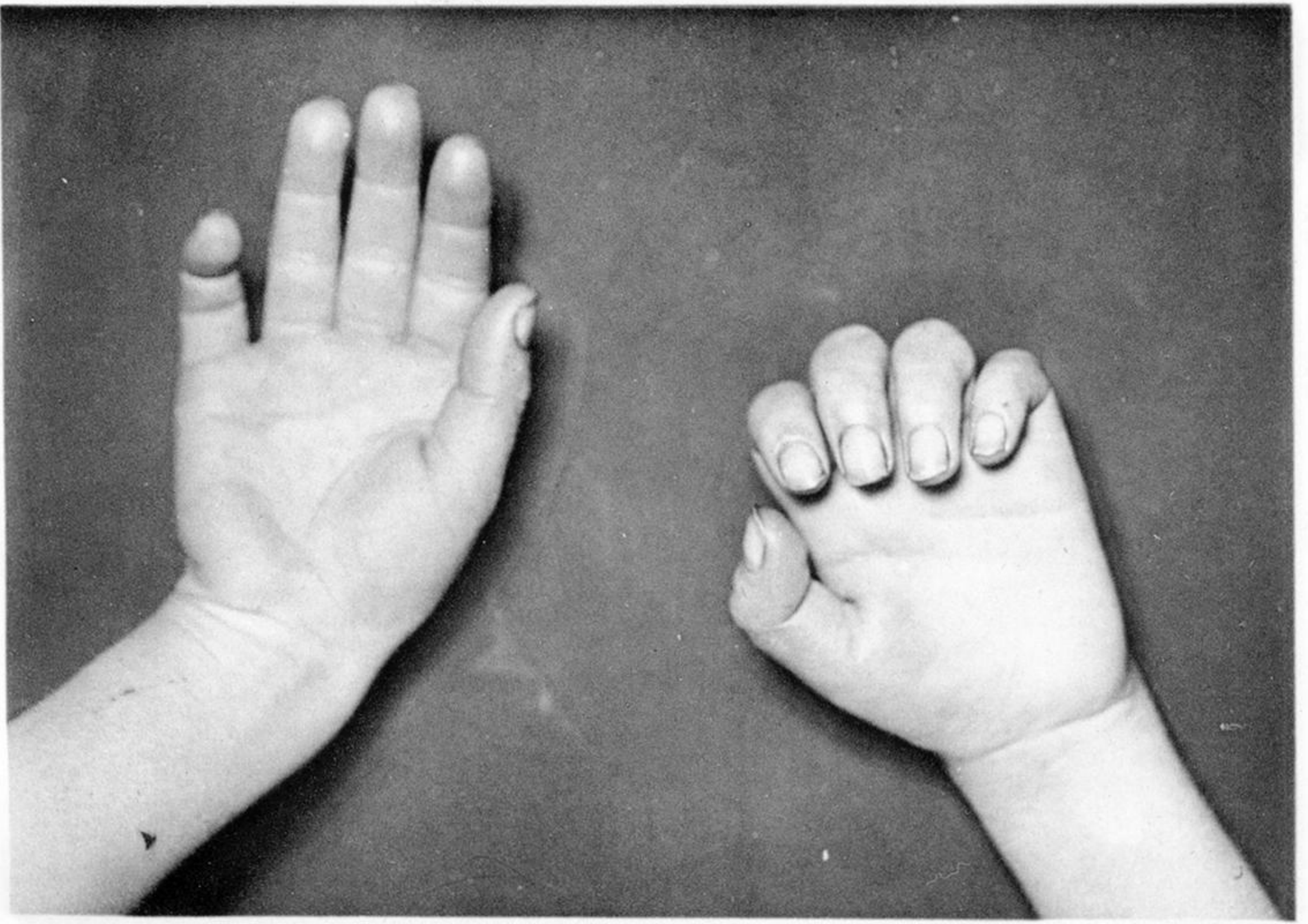


Fig. 2.

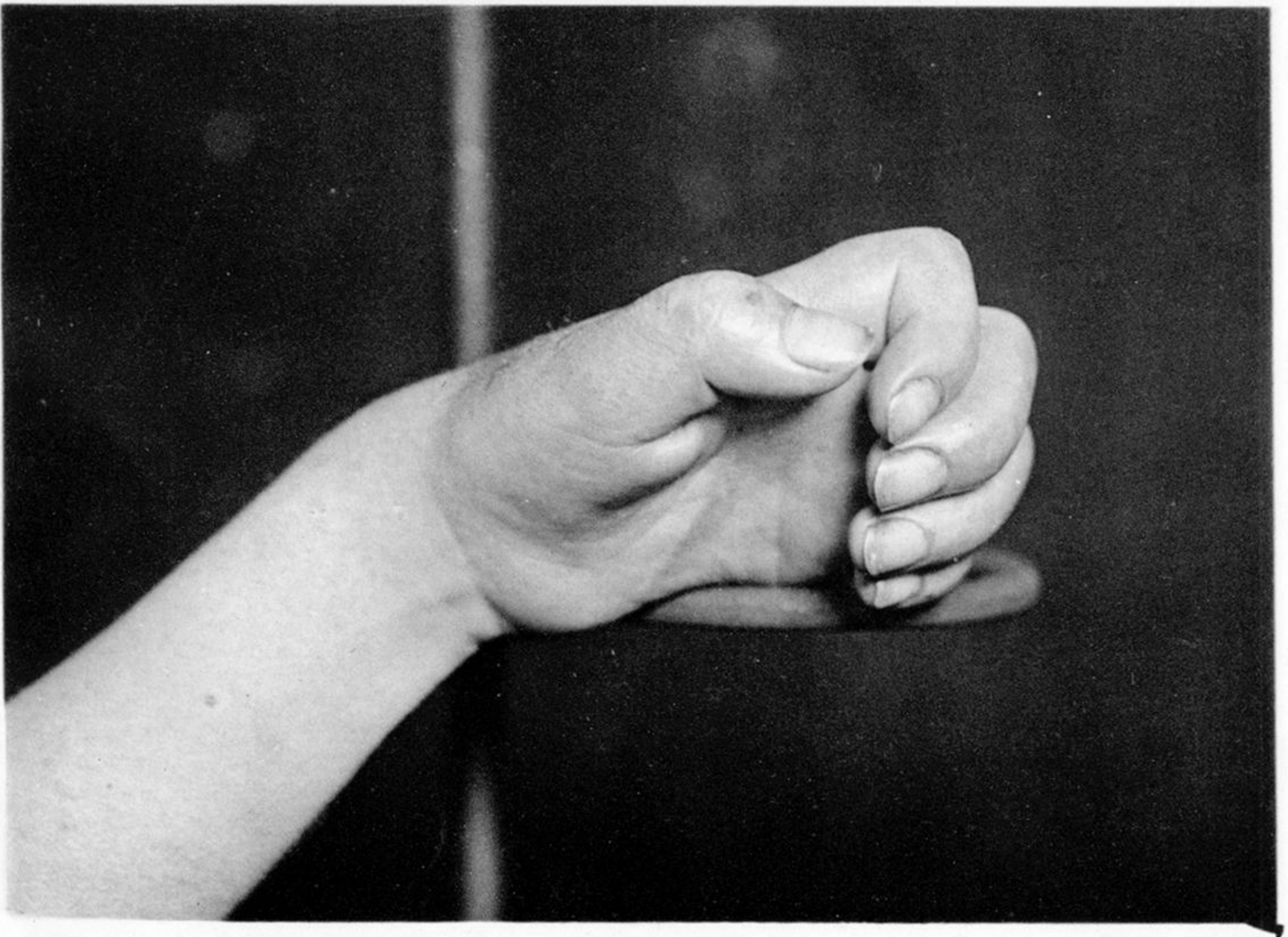

PLATE 6.

Fig. 1. Hand of Case III., with right hand for comparison, before operation. Two months after fracture at elbow joint. Shows position in which fingers and thumb were carried, and the atrophy of the thenar and hypothenar eminences. $\frac{1}{2}$ nat. size.

Fig. 2. Same. Shows hollowing out of palm and flexion at wrist. $\frac{2}{3}$ nat. size.

Fig. 1.

Fig. 2.

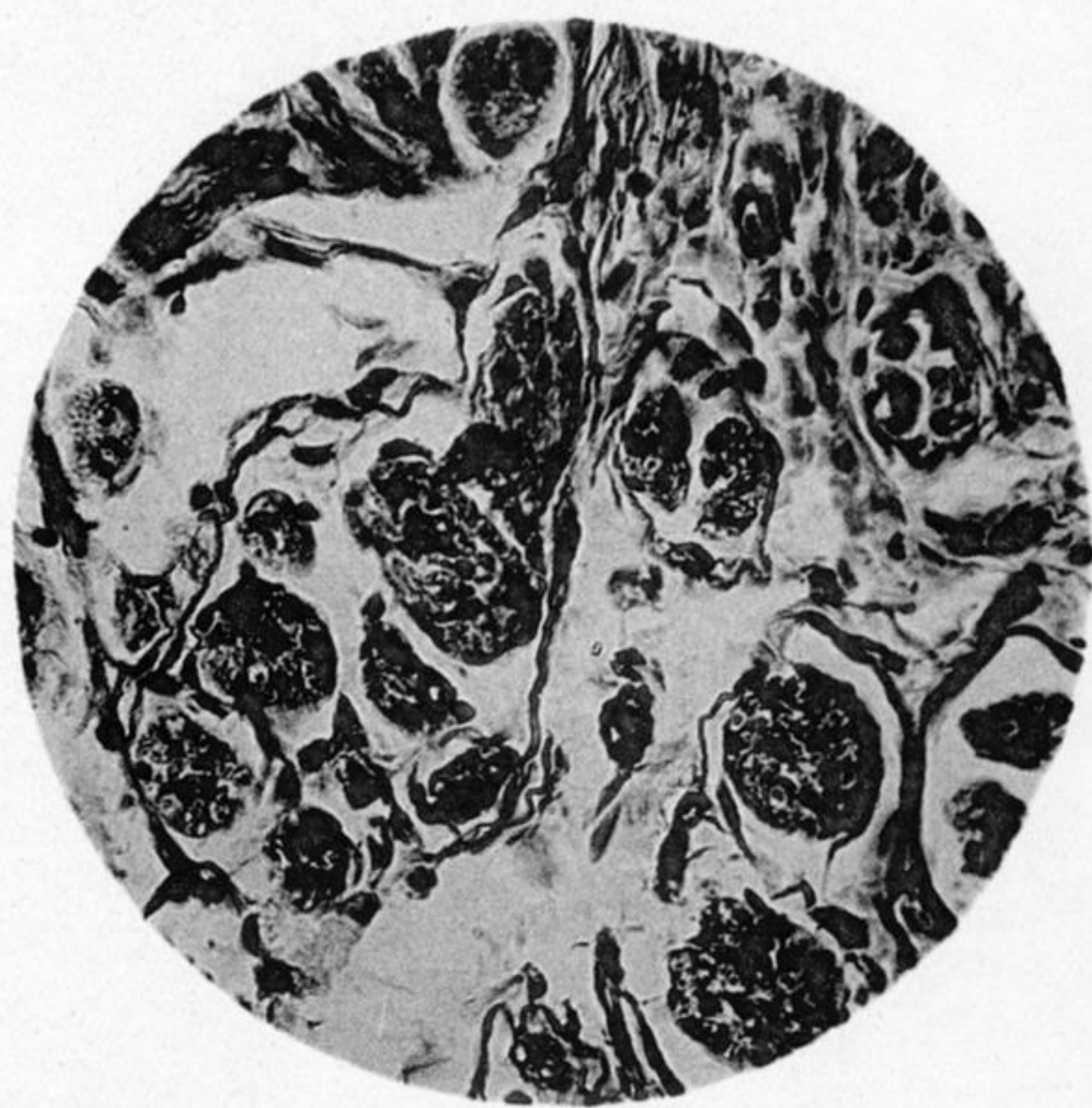
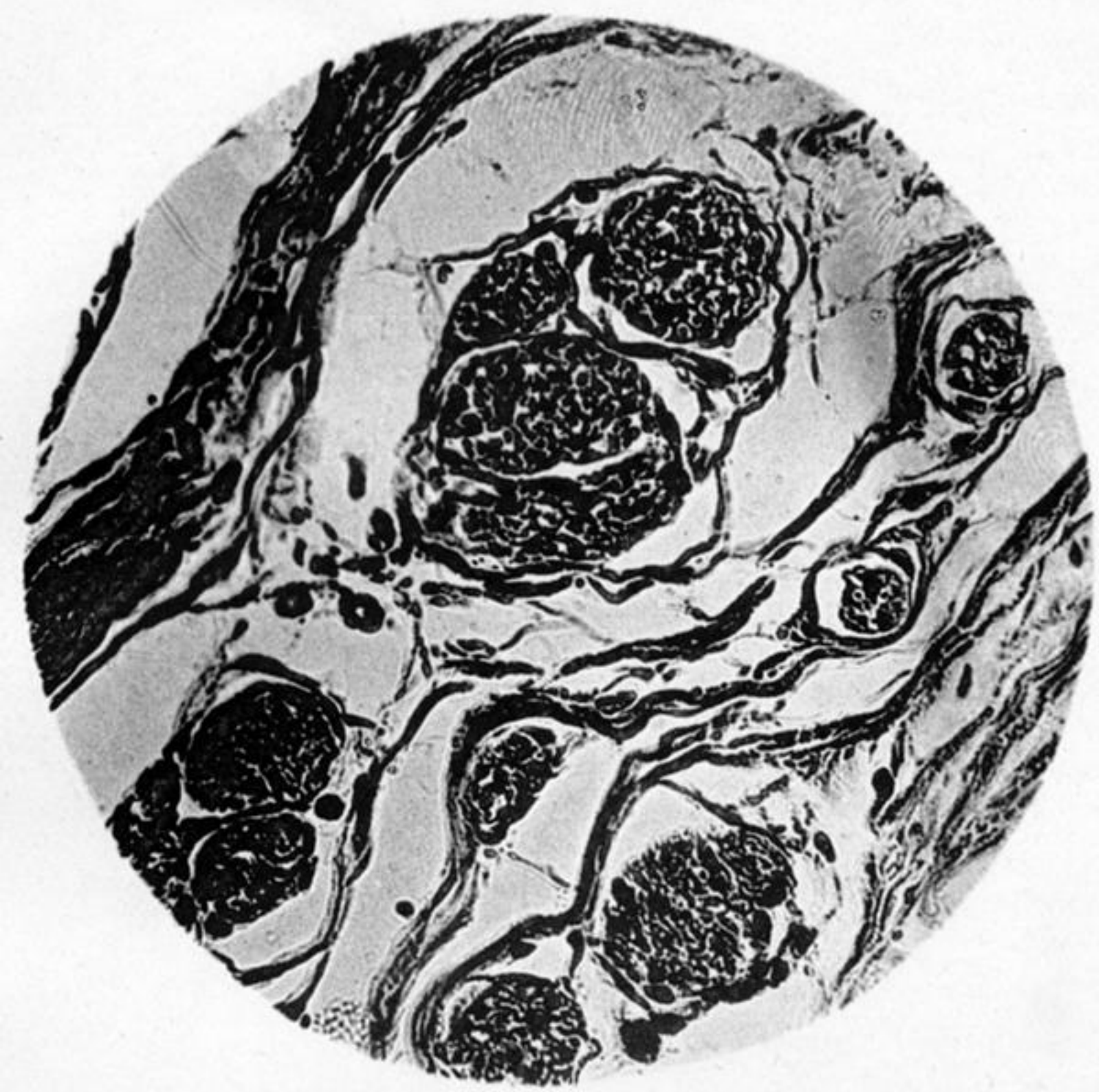


Fig. 3.

Fig. 4.

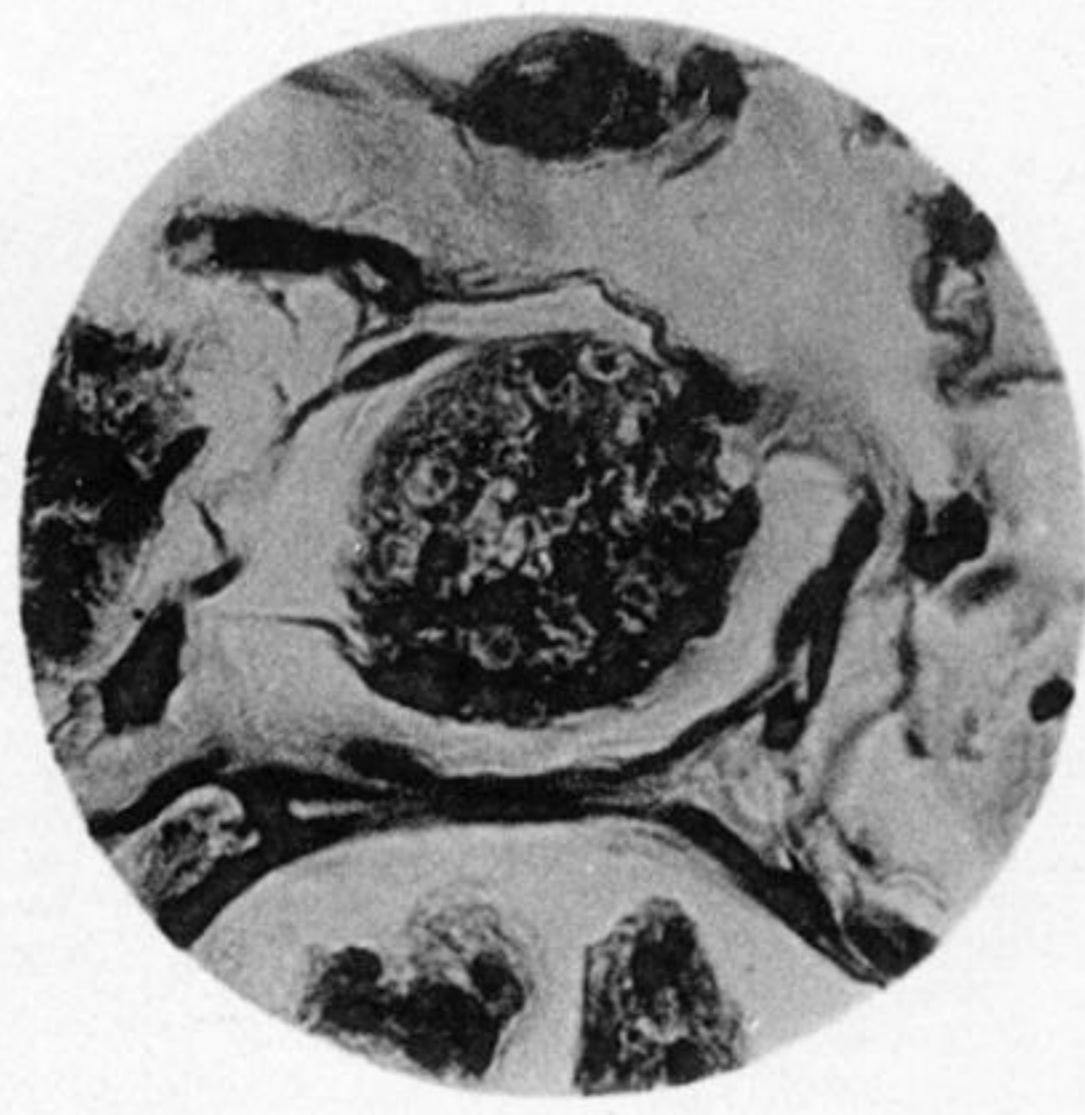
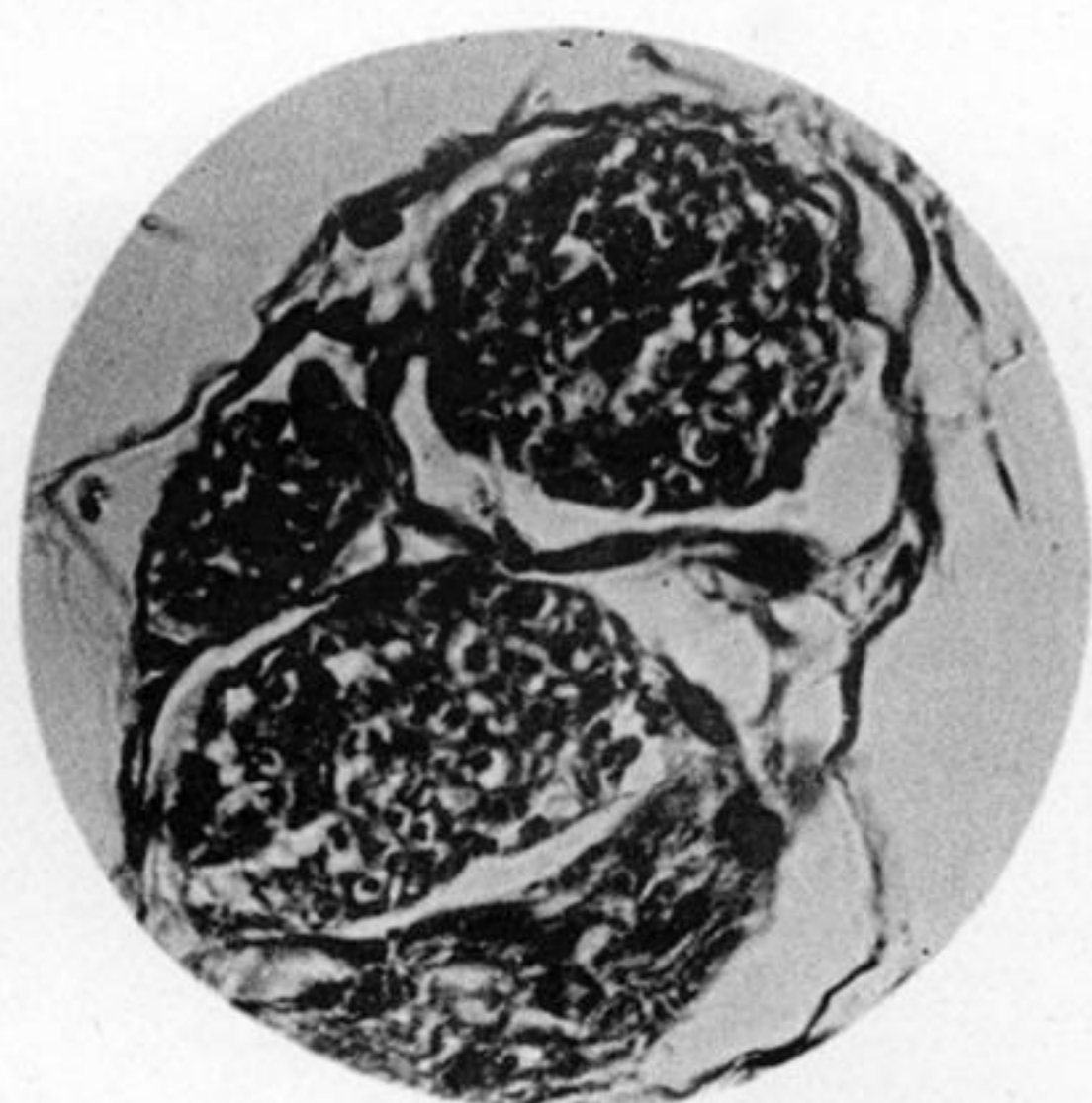


Fig. 5.

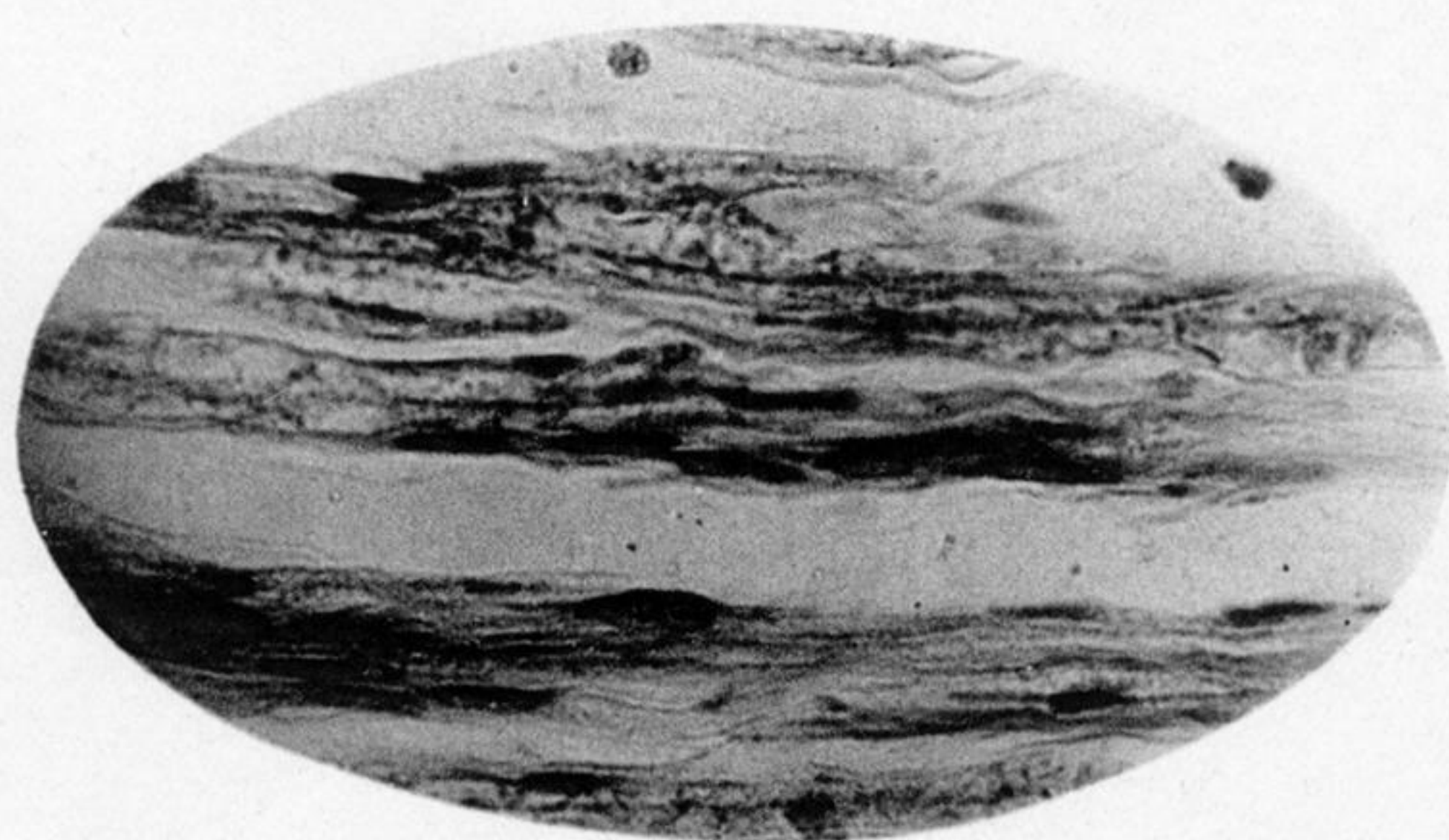


PLATE 7.

- Fig. 1. Longitudinal section central bulb, ulnar nerve. Case I. Near centre three small bundles grouped together, and separated by layers of connective tissue, and each containing an enormous number of young nerve fibres, in which are displayed the axis-cylinders, each surrounded by a clear zone. A bundle also shown longitudinally, the fibres showing in parts the delicate axis-cylinder with granular deposit of myeline around, and also oval nuclei. ZEISS, Obj. D. $\frac{340}{1}$. Cf. figs. 2 and 3.
- Fig. 2. Longitudinal section bulb from peripheral end of ulnar. Case I. Shows young nerve fibres identical in appearance with those in central bulb (fig. 1). Many nerve fibres in each bundle. Distinct axis-cylinders. The nuclei in the bundles are distinct from the nerve fibres. ZEISS, Obj. D. $\frac{340}{1}$. Cf. fig. 4.
- Fig. 3. Same as in fig. 1. (Central end.) Part of largest bundle taking an oblique course. ZEISS, Obj. F. $\frac{600}{1}$.
- Fig. 4. Same as in fig. 2. (Peripheral end.) Shows young nerve fibres with axis-cylinders and clear surrounding zone, and many nuclei interspersed among fibres. ZEISS, Obj. F. $\frac{600}{1}$.
- Fig. 5. Longitudinal section ulnar nerve at entrance to central bulb. Case I. Transition from old to young nerve fibres. Shows old fibre diminishing and giving place to young nerve fibres with spindle-shaped nuclei. At one side a bundle of young nerve fibres less than double the diameter of an old fibre, showing young nerve fibres with axis-cylinders, granular myeline deposit, and spindle-shaped nuclei, attached to sides of young fibres. ZEISS, Obj. F. $\frac{600}{1}$.

Fig. 1.

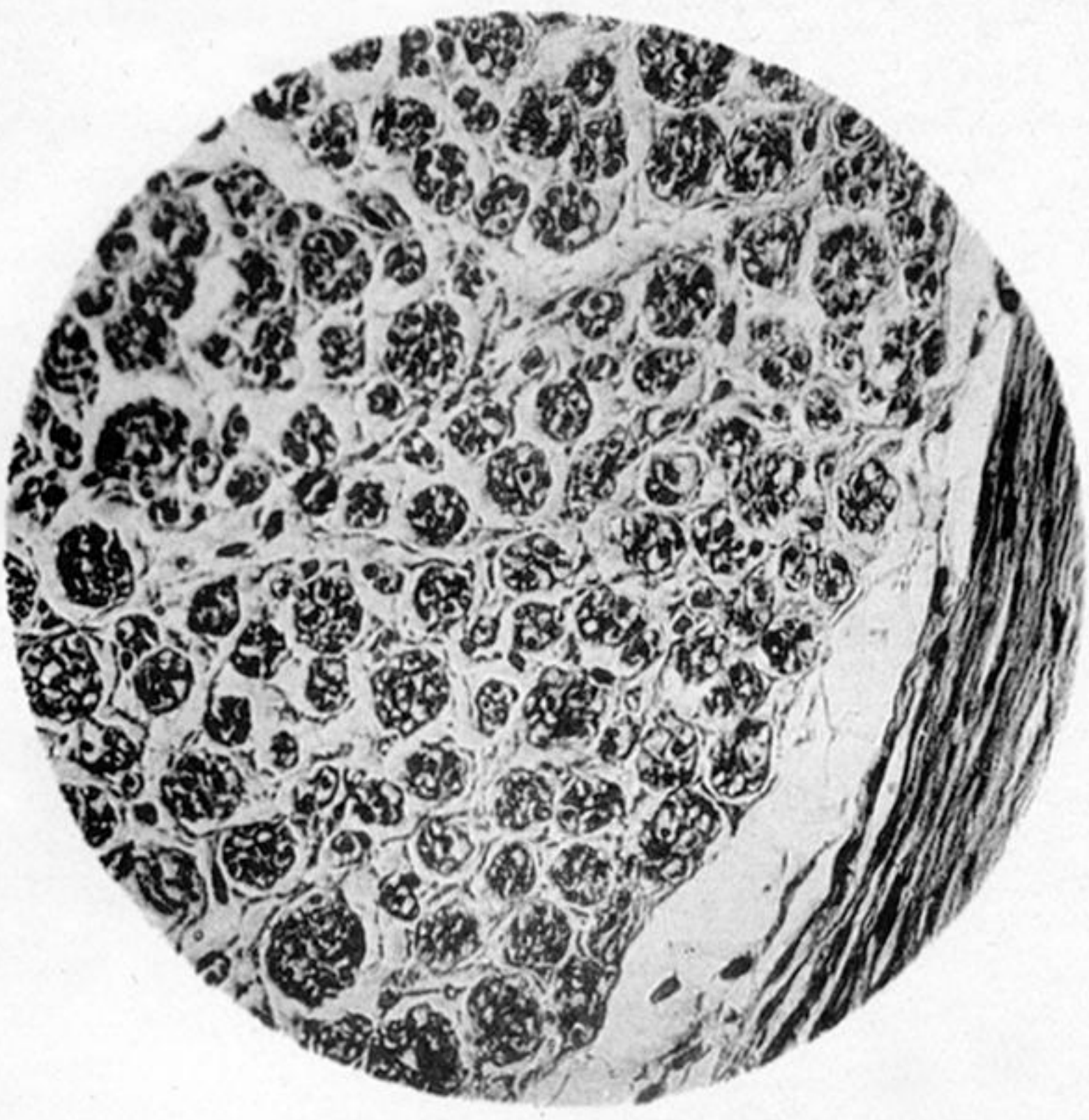


Fig. 2.

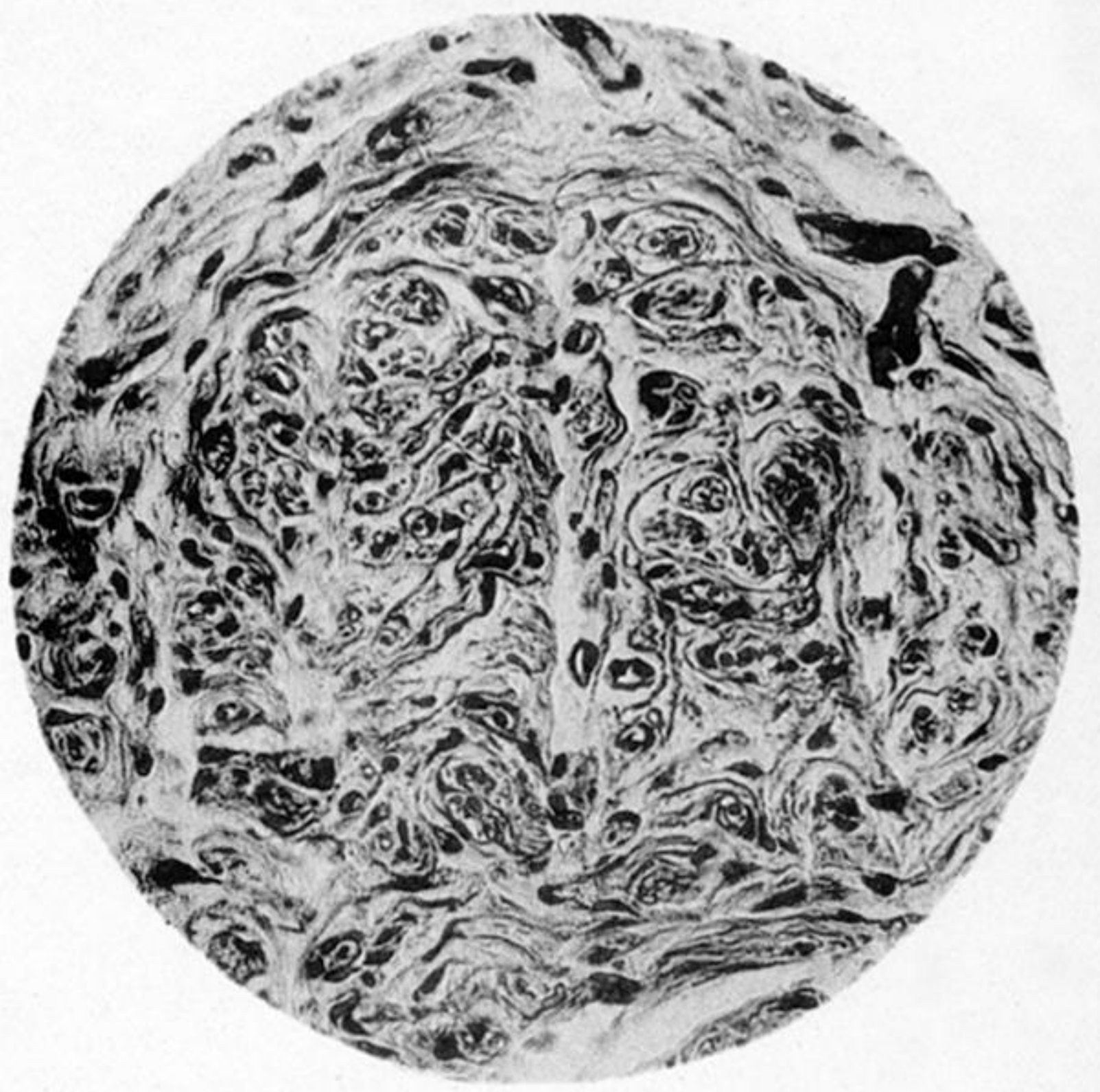


Fig. 3.

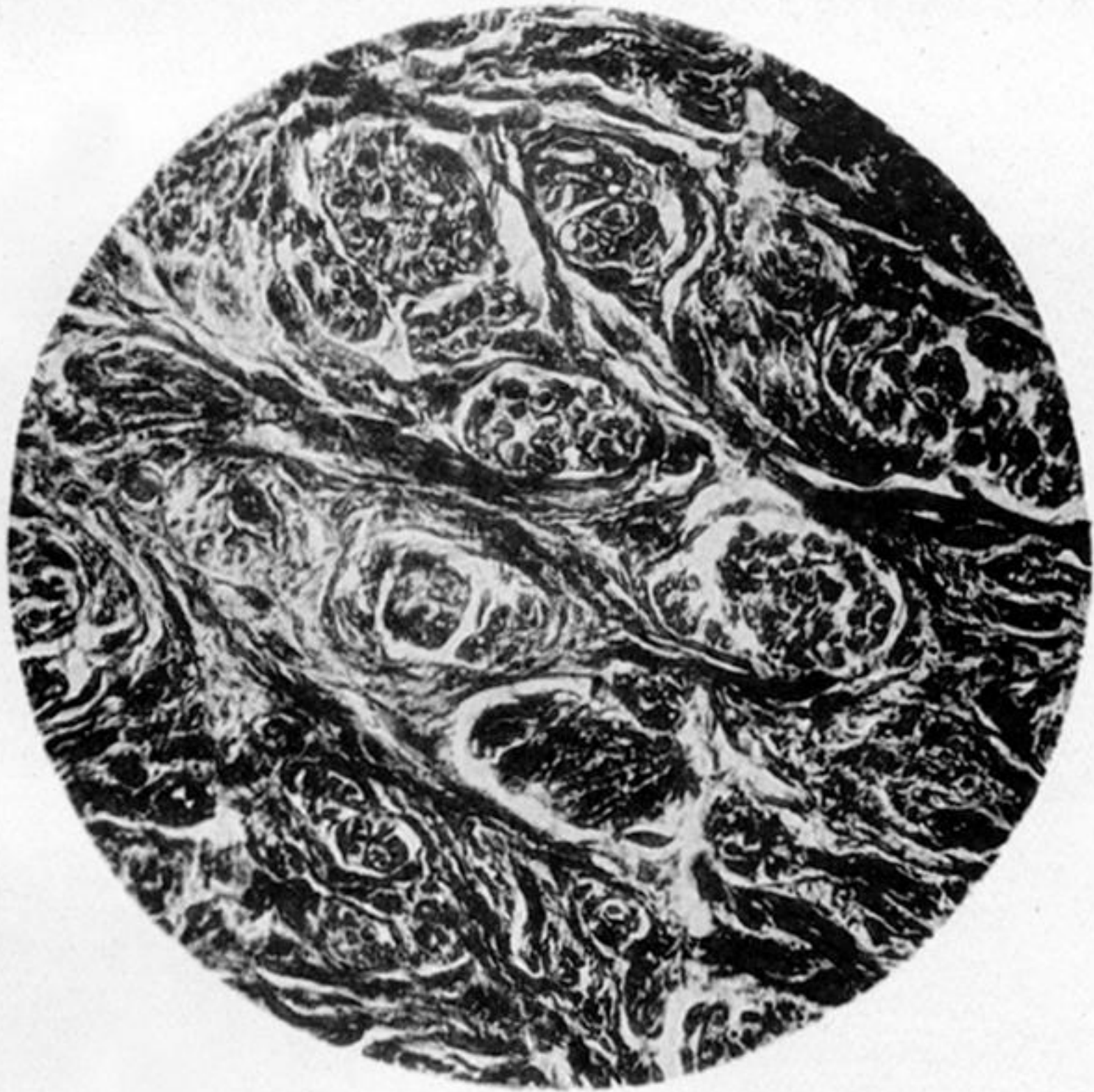

Fig. 4.

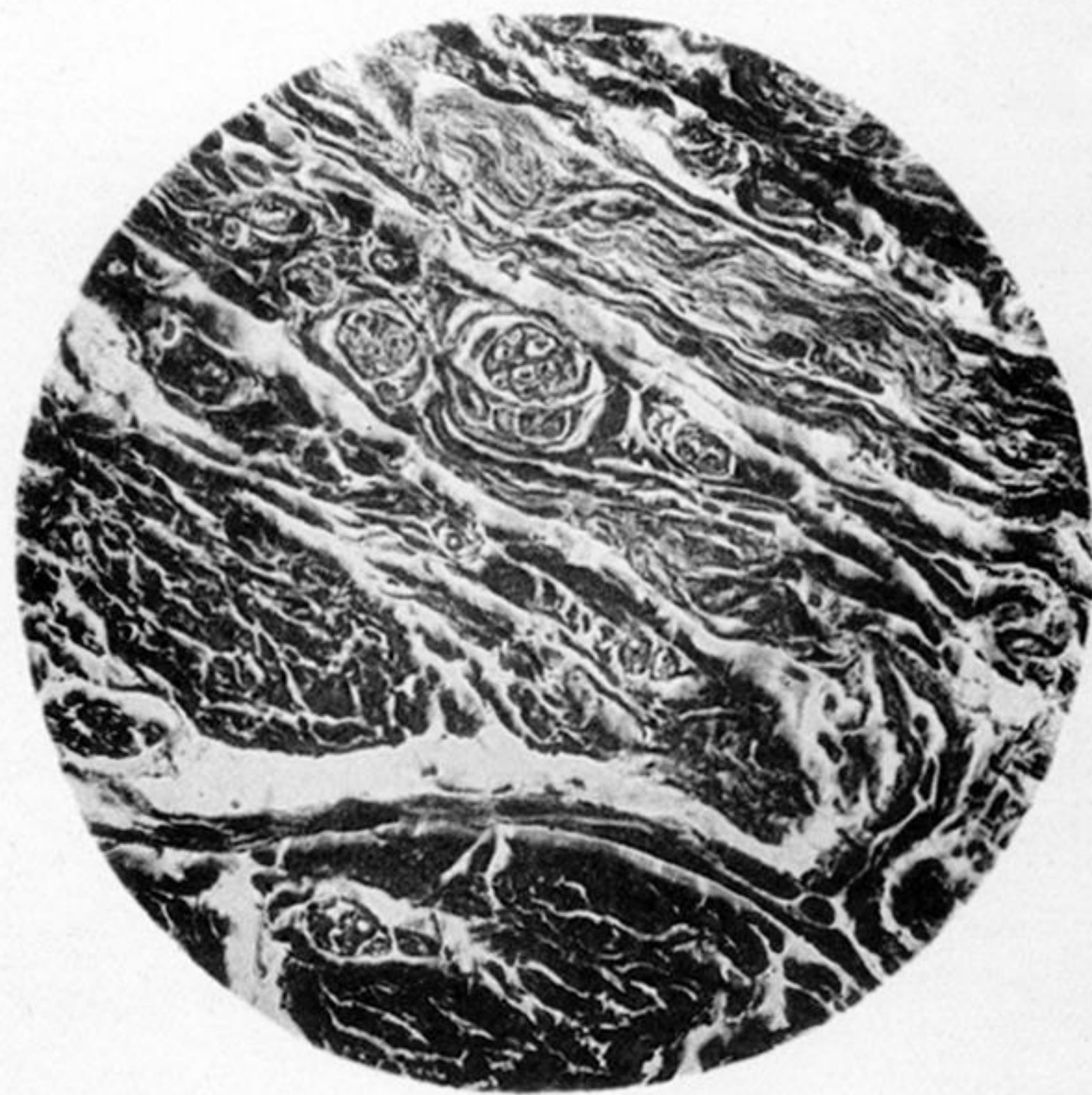

Fig. 5.

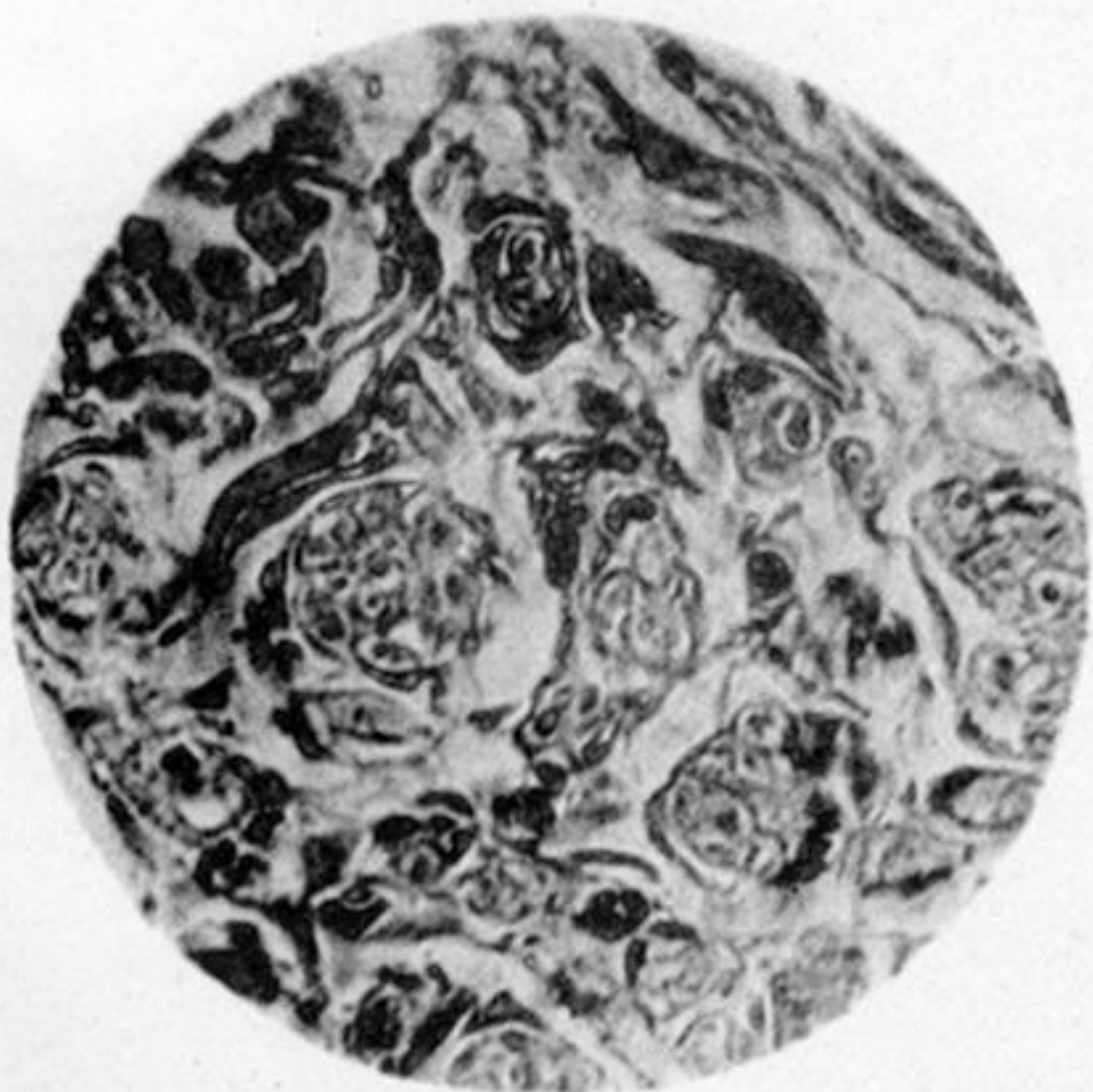


Fig. 6.

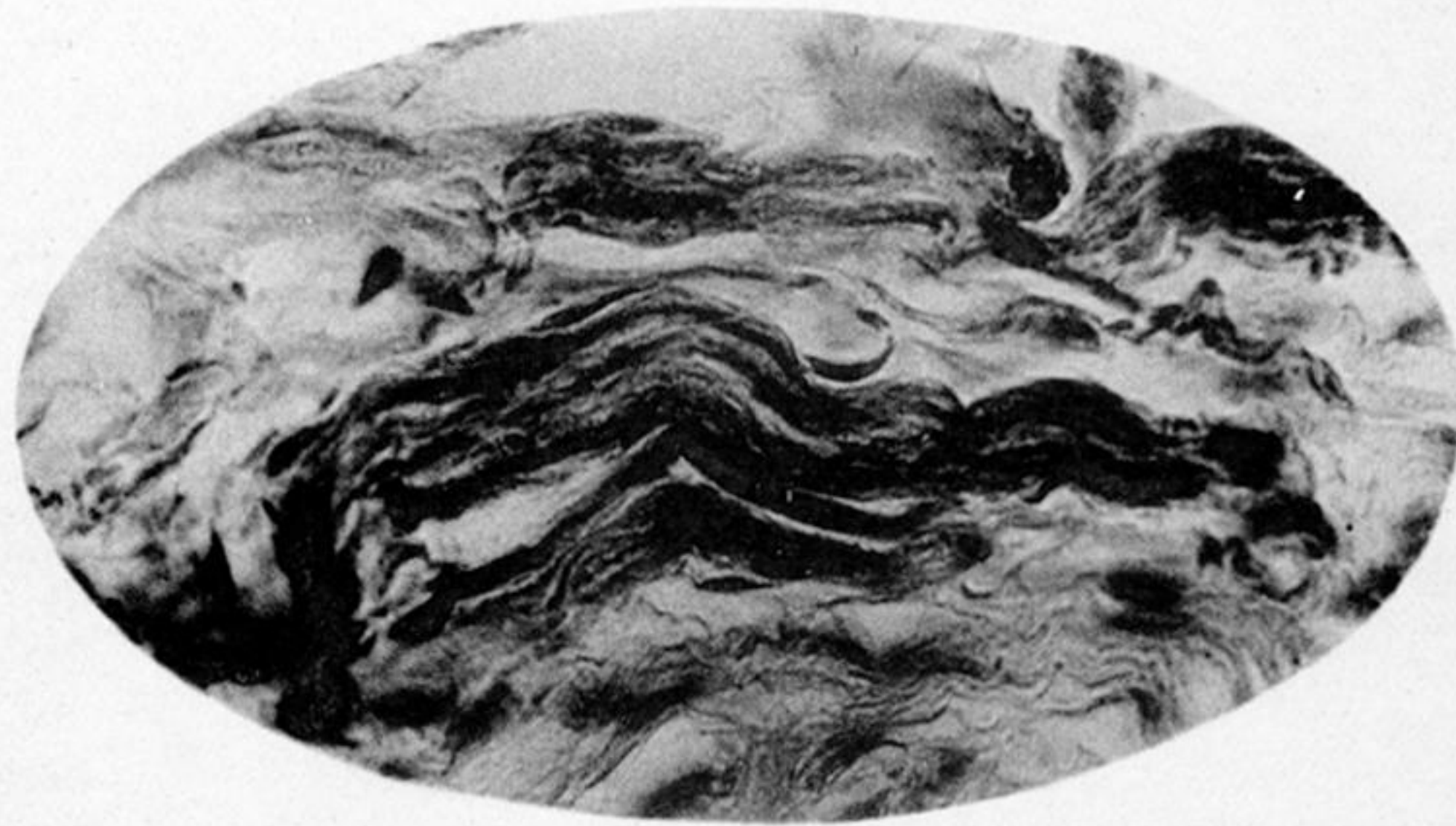


PLATE 8.

Fig. 1. Transverse section of ulnar nerve eighteen months divided, immediately proximal to the bulb on central end. Case IV. Portion of fasciculus. Shows normal perineurium and small bundles of young nerve fibres arranged like single old fibres. In some a delicate sheath surrounding the bundle. ZEISS, Obj. D. $\frac{340}{1}$.

Fig. 2. Transverse section, base of cone from peripheral end of ulnar, eighteen months divided. Case IV. Shows compact tissue with small bundles of young nerve fibres cut transversely. Nuclei in the bundles besides nerve fibres. ZEISS, Obj. D. $\frac{340}{1}$.

Fig. 3. Transverse section, proximal end of intercalary segment uniting ends of median. Case I. Dense groundwork of fibrous tissue containing in its meshes bundles of young nerve fibres showing nuclei. ZEISS, Obj. D. $\frac{340}{1}$.

Fig. 4. Transverse section, distal end of same intercalary segment. Dense masses of fibrous tissue with a few bundles of transversely-cut young nerve fibres, and one bundle of young nerve fibres longitudinally cut. ZEISS, Obj. D. $\frac{340}{1}$.

Fig. 5. Longitudinal (radial) section same intercalary segment. A portion at centre of mass. Shows several bundles of young nerve fibres transversely cut. ZEISS, Obj. F. $\frac{600}{1}$.

Fig. 6. Another portion same section. Also at centre of mass. A bundle of young nerve fibres seen longitudinally. Shows axis-cylinders and commencing myelination deposit. ZEISS, Obj. F. $\frac{600}{1}$.

Fig. 1.

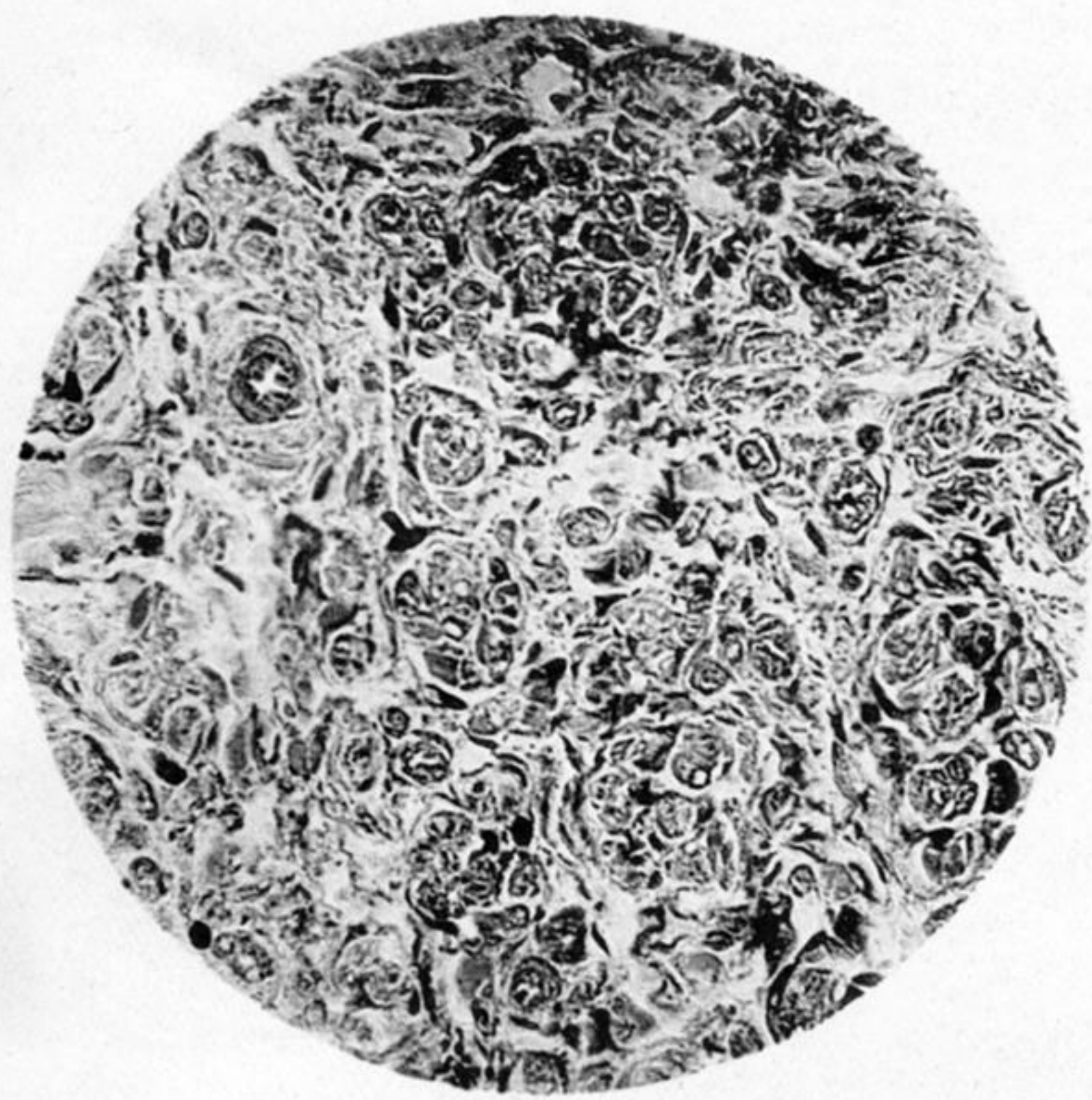


Fig. 2.

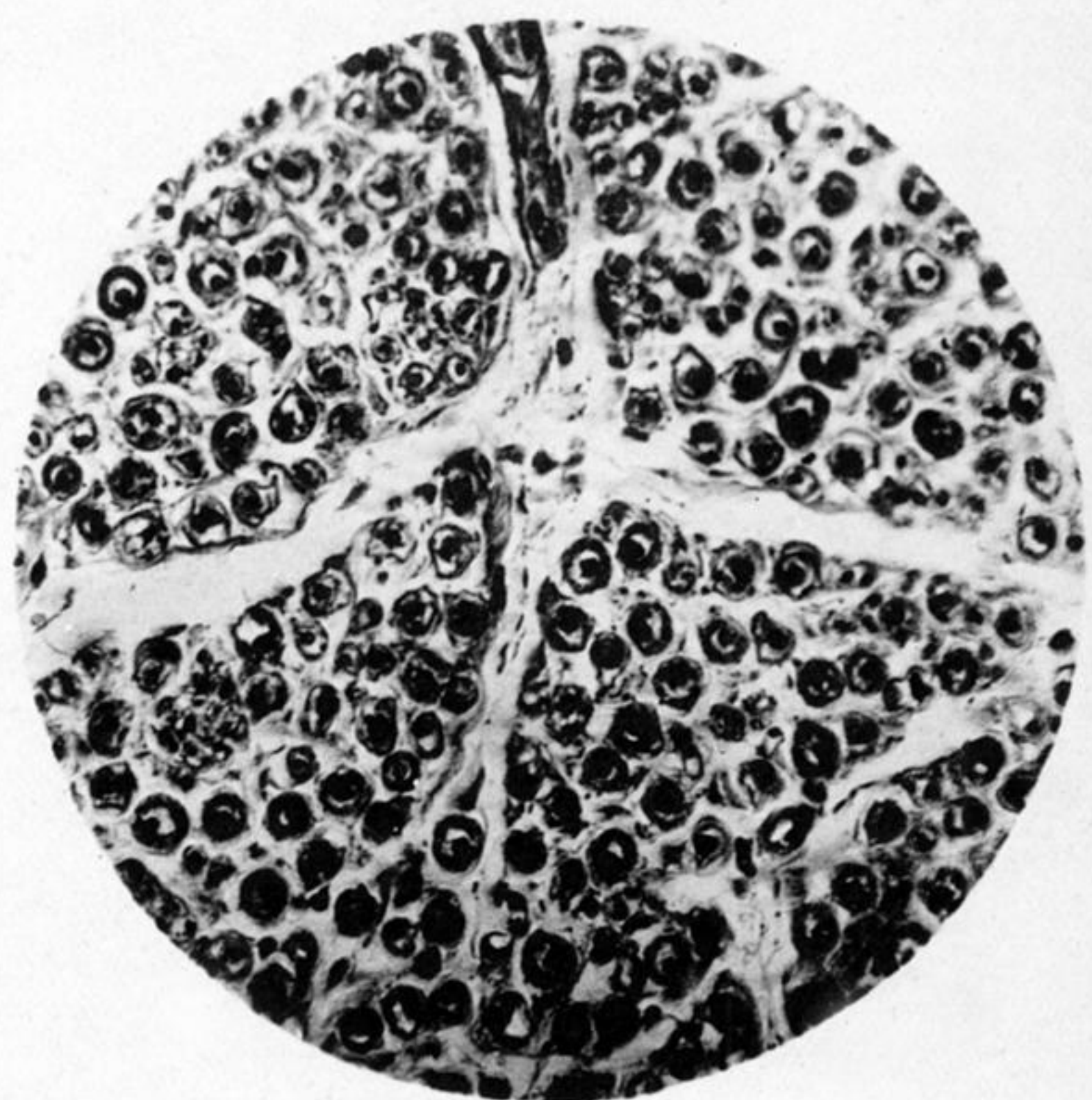


Fig. 3.

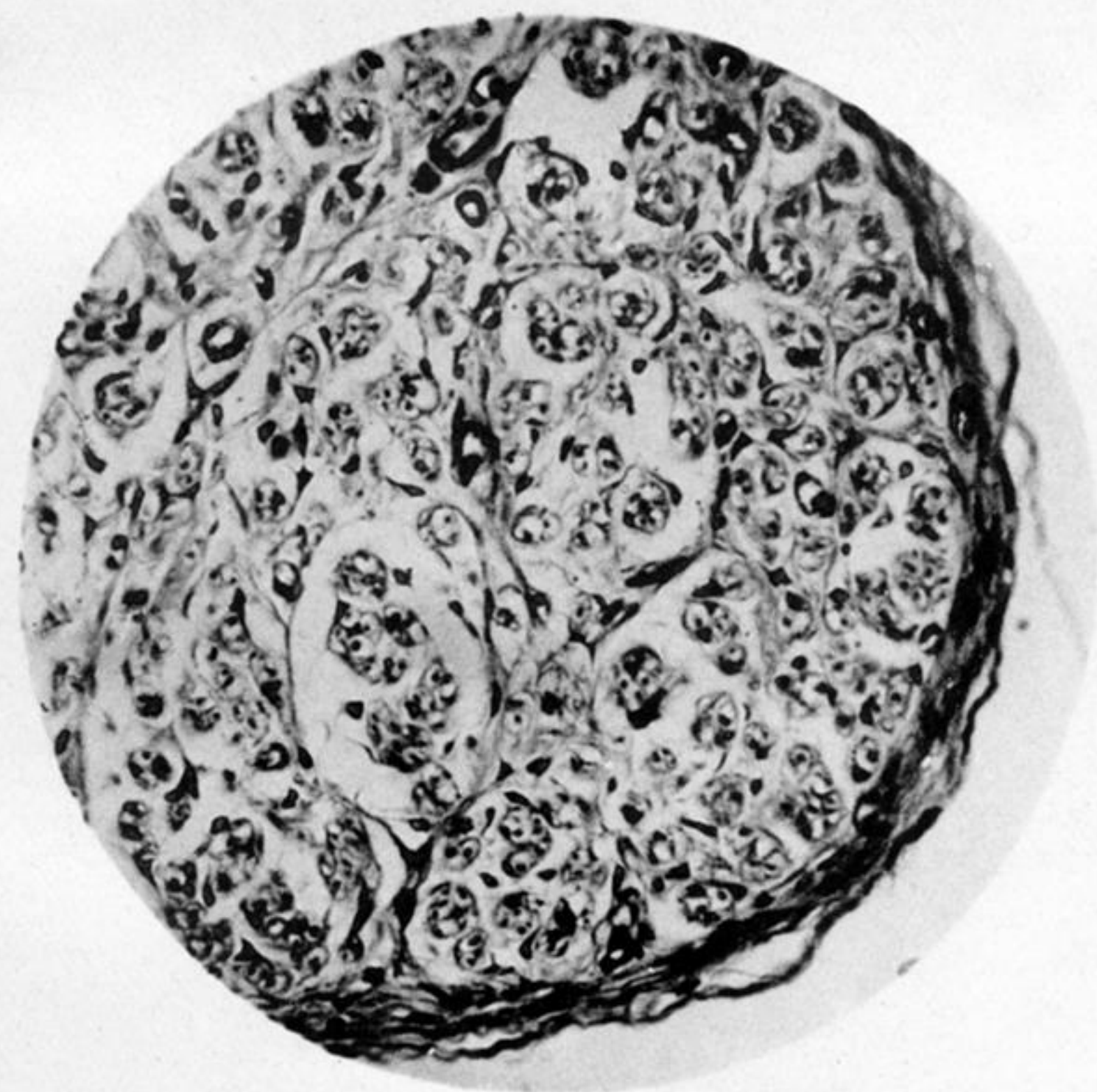


Fig. 4.



Fig. 5.

Fig. 6.

Fig. 7.

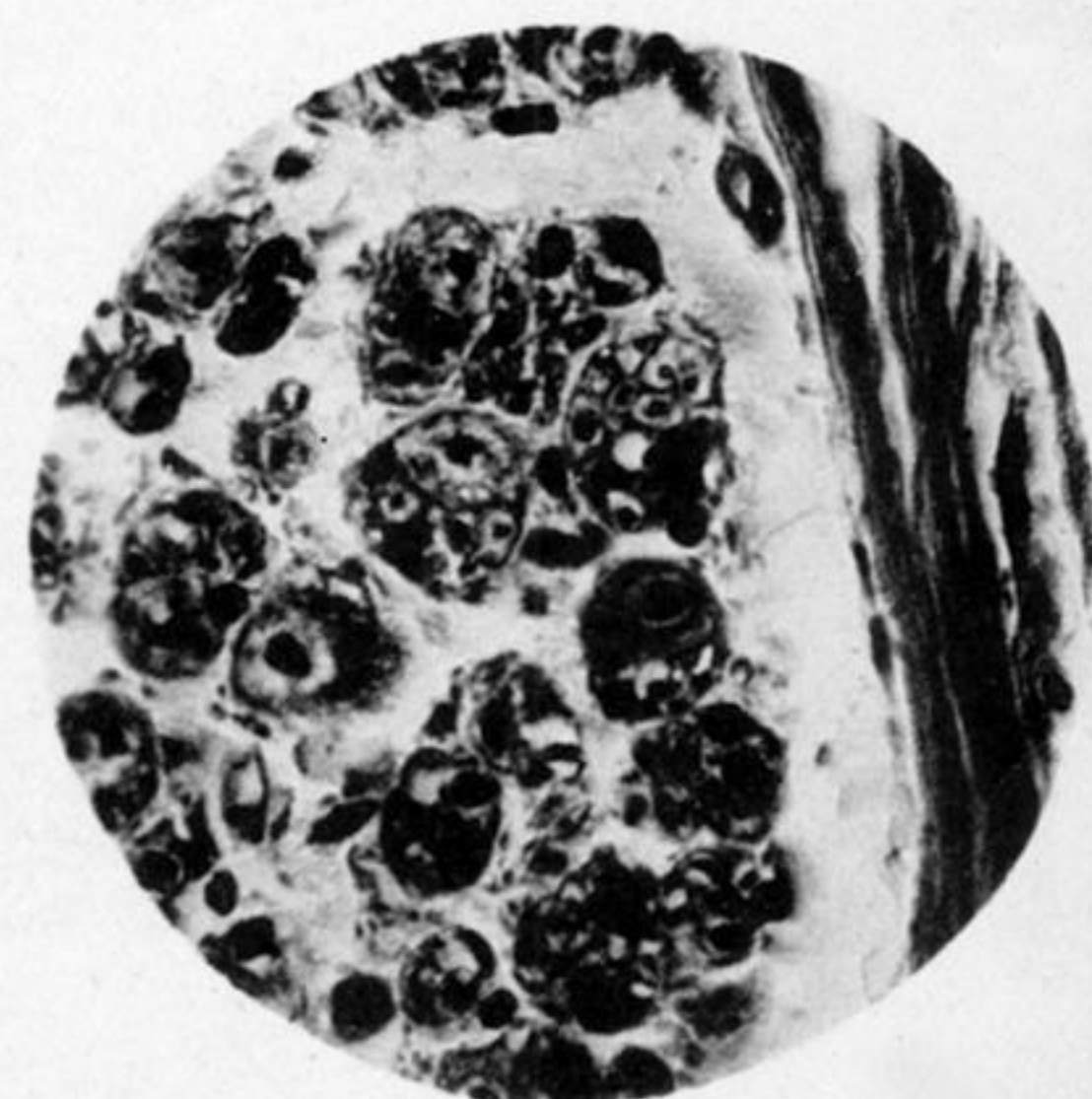
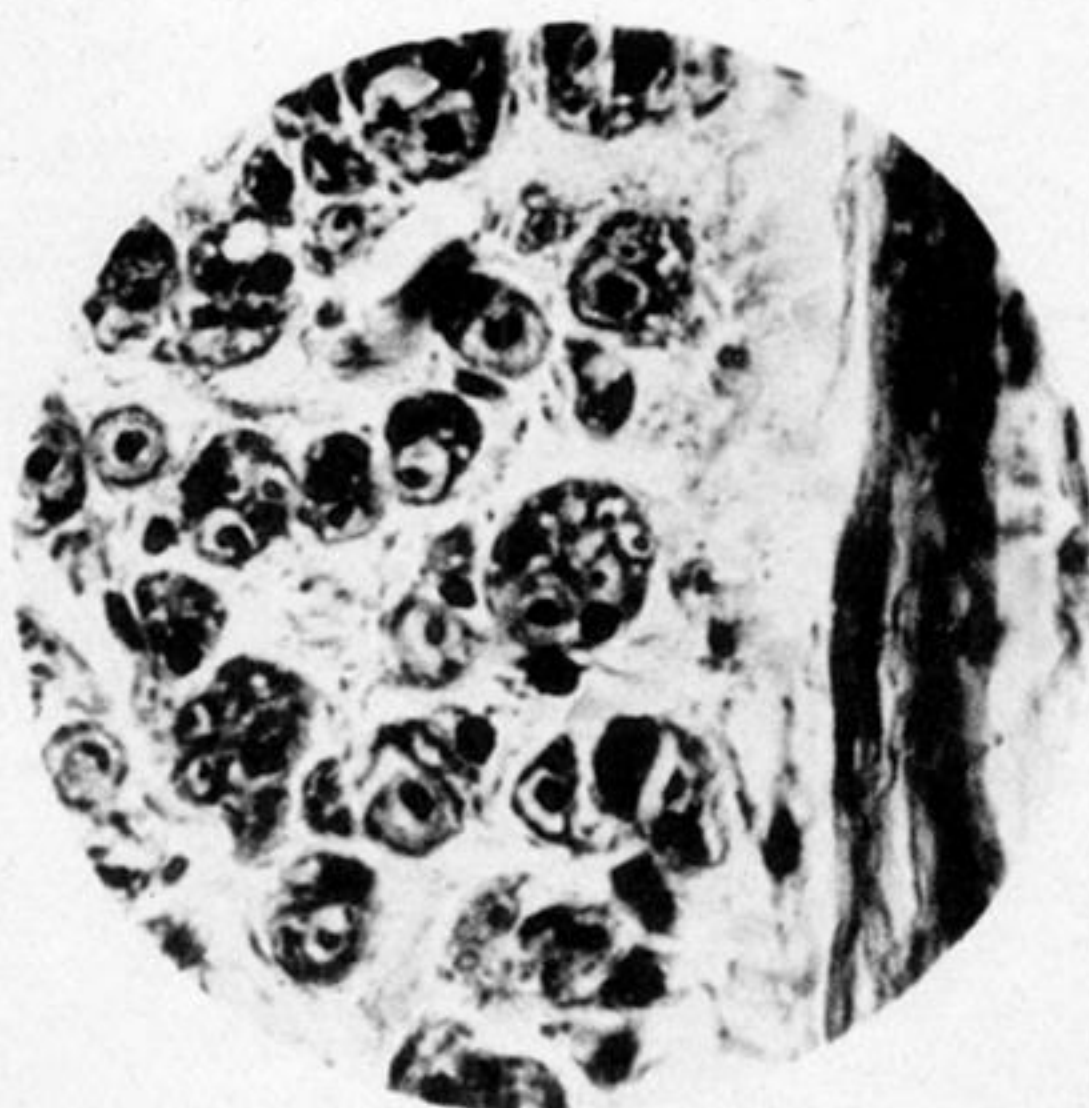
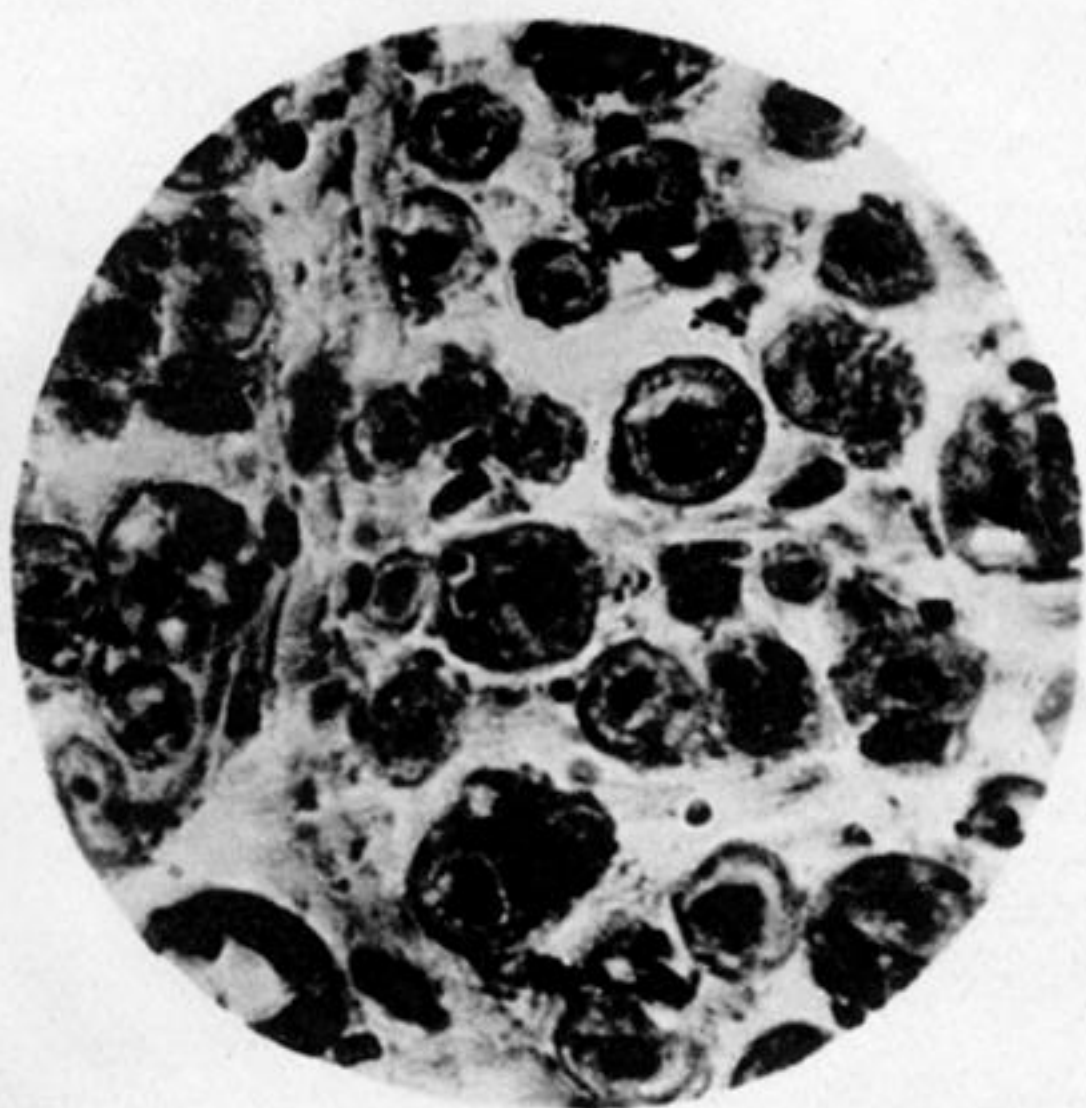


PLATE 9.

Fig. 1. Transverse section, intercalary segment—distal end. Another part of same section shown in Plate 8, fig. 4. Shows numerous very small bundles of young nerve fibres. ZEISS, Obj. D. $\frac{340}{1}$.

Fig. 2. Transverse section, proximal end of portion excised from median nerve. Case III. Nerve compressed at seat of fracture. Shows old myeline nerve fibres. Same appearance as section of normal nerve treated by same methods. ZEISS, Obj. D. $\frac{340}{1}$.

Fig. 3. Transverse section, distal end of same portion of nerve. Shows normal perineurium, and small bundles of young nerve fibres, grouped as the single old fibres in fig. 2. Many of the bundles contain also nuclei and are surrounded by a delicate sheath. ZEISS, Obj. D. $\frac{340}{1}$.

Fig. 4. Longitudinal section through point of transition from old to young nerve fibres in portion removed from musculo-spiral nerve. Case III. Two old fibres are seen terminating and giving place each to a bundle of young nerve fibres. ZEISS, Obj. F. $\frac{600}{1}$.

Fig. 5. Transverse section same. Near centre, two very large old fibres, one of which shows at one side a slight thickening representing the nucleus and protoplasm of the sheath of SCHWANN, while the other shows at one side a large circular nucleus with two young nerve fibres at its side, all three structures lying between the myeline sheath and sheath of SCHWANN. ZEISS, Obj. F. $\frac{600}{1}$.

Fig. 6. Same section. Portion of perineurium, and near centre, a bundle of young nerve fibres with two nuclei and the old myeline sheath and axis-cylinder at one side. ZEISS, Obj. F. $\frac{600}{1}$.

Fig. 7. Same section. Near centre a bundle of young nerve fibres, with remains of old fibre at one side. ZEISS, Obj. F. $\frac{600}{1}$.